

REVASCULARIZATION OF THE TONGUE IN ADVANCED SUPRAGLOTTIC LARYNGEAL CARCINOMA: A CHALLENGING CASE

Head and Neck Surgery

Submitted : 02.02.2019

Accepted : 13.03.2019

Published : 20.03.2019

Faruk Kadri Bakkal¹, Barış Karakullukçu²

¹ Uşak Eğitim ve Araştırma Hastanesi

² The Netherlands Cancer Institute/Antoni van Leeuwenhoek Hospital, Amsterdam

Özet

İLERİ EVRE SUPRAGLOTTİK LARİNK KANSERİNDE DİLİN REVASKÜLARİZASYONU: ZORLU BİR OLGU

Dilin rekonstrüksiyonu baş boyun onkolojisindeki en zorlu durumlardan biridir. Dilin korunması bütün rekonstrüksiyon yöntemlerine göre üstündür. Uygun vakalarda mikrocerrahi revaskülarizasyon bu amaca yönelik tercih edilebilecek bir seçenektir. Bu yazıda malign tümör cerrahisi nedeniyle her iki lingual arteri kesilen ve sağ tarafta başarılı bir mikrocerrahi revaskülarizasyon yapılan bir olgu sunulmuştur. Hasta cerrahi sonrası sorunsuz iyileşmiş olup dili takip süresince canlı kalmıştır.

Anahtar kelimeler: Dil, tümör, lingual arter, revaskülarizasyon

Abstract

REVASCULARIZATION OF THE TONGUE IN ADVANCED SUPRAGLOTTIC LARYNGEAL CARCINOMA: A CHALLENGING CASE

Reconstruction of the tongue remains one of the most challenging conditions in head and neck oncology. Preserving the tongue is superior to any kind of reconstruction. In appropriate cases microsurgical revascularization is an eligible option for this purpose. In this paper we present a case in which both lingual arteries sectioned due to malignant tumor surgery and successfully revascularized microsurgically on the right side. The patient had an uneventful recovery and the tongue remained viable in the follow-up period.

Keywords: Tongue, tumor, lingual artery, revascularization

Introduction

Preserving the tongue and its functions is essential for a good quality of life [1-2]. In tumor surgery, sacrifice of both lingual arteries surgically is defined as unresectable, due to causing tongue necrosis. Revascularization of the tongue with micro vascular techniques is efficacious in selected cases where the blood supply to this organ is interrupted [3]. In the literature, there are few reports of such reconstruction. In this paper we describe a case, successfully revascularized microsurgically of the right lingual artery, following a surgical resection for a recurrent laryngeal carcinoma ascending up to the base of the tongue.

Case Report

A 63-year-old man presented with T3N2M0 squamous cell carcinoma of the supraglottic larynx was admitted with complaints of hoarseness, swallowing disorders and aspiration problems. He was treated with primary chemoradiation therapy. He applied one year later with a recurrence swelling, predominantly involving the left side of the tongue base with extension to left ary-epiglottic fold, the left side of the epiglottis and the larynx. The vocal cords on both sides were free of tumor. There was no evidence of pathologic lymphadenopathy or distant metastasis in the PET/CT-scan and MRI of the neck. Biopsy indicated a recurrent squamous cell carcinoma. The patient underwent a total laryngectomy, partial pharyngectomy and resection of the tumor involving the base of the tongue.

Corresponding Author: Faruk Kadri Bakkal, Uşak Eğitim ve Araştırma Hastanesi Cumhuriyet mah. Orhan Dengiz bulvarı. NO:128/2 Merkez/UŞAK. farukbakal@yahoo.com

Bakal FK, Karakullukçu B. İleri evre supraglottik larinks kanserinde dilin revaskülarizasyonu: zorlu bir olgu. ENTcase. 2019;5(1):12-15

As expected, the left lingual artery and hypoglossal nerve was found to be surrounded by the tumor at surgery. Both of them had to be sectioned during dissection. At surgery we noticed that the right lingual artery was adherent to the tumor, but the artery was not invaded by it. We had to cut the right lingual artery from 10 millimeter distal to the external carotid artery during dissection for clear surgical margins. After completion of all laryngectomy and tumor resection, the proximal and distal stumps of the right lingual artery connected with a micro anastomosis technique (Figure 1: A-B-C).

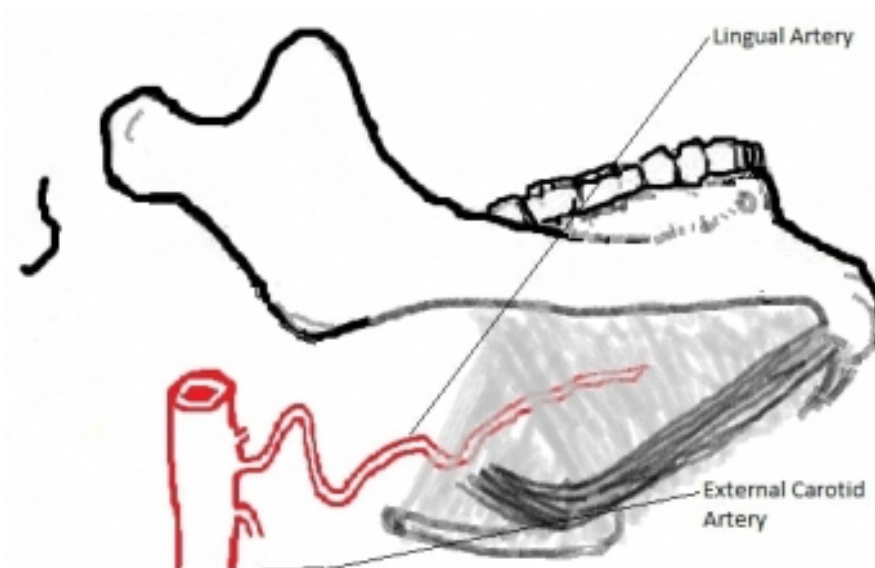


FIGURE 1A

Figure 1A

Demonstrating the natural voluted formation of the lingual artery

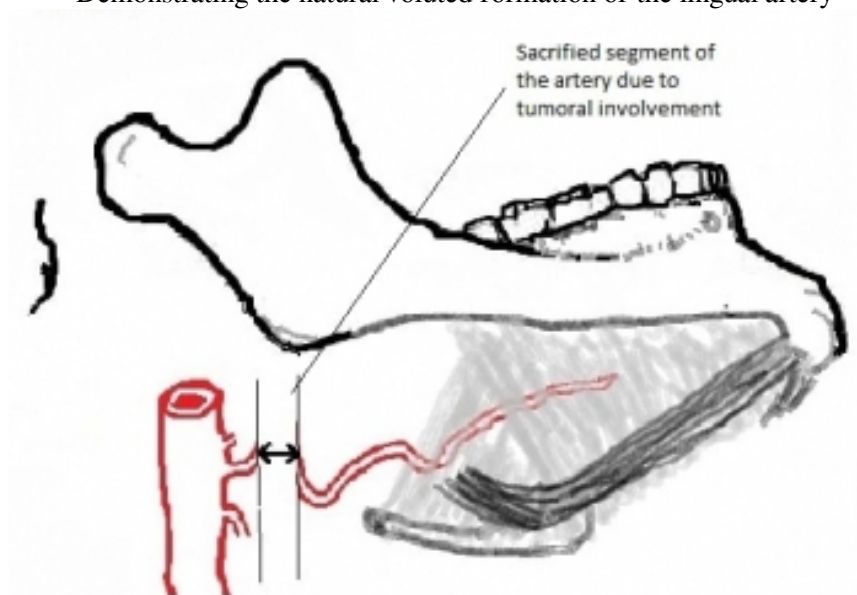


FIGURE 1B

Figure 1B

Demonstrating the 1 cm resected part of the artery due to tumor

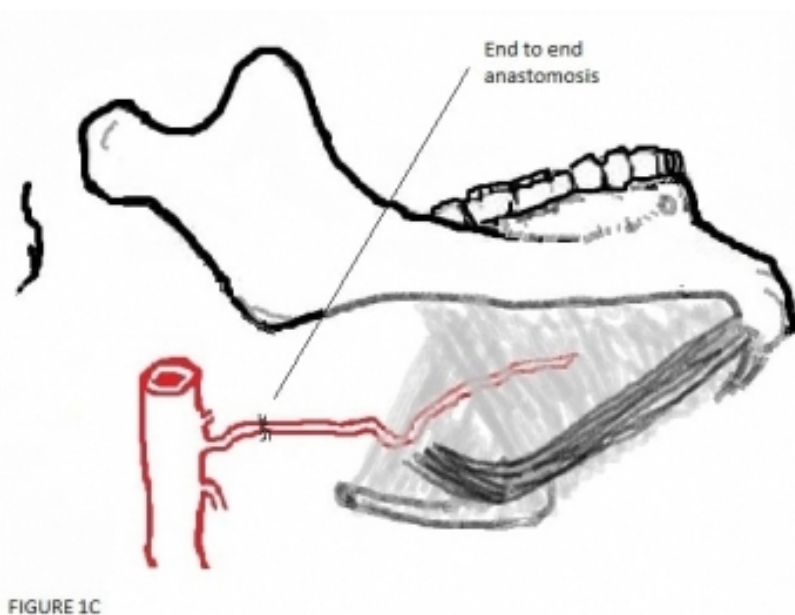


Figure 1C
Demonstrating the end to end anastomosis between lingual artery stumps

The voluted structure of the lingual artery allowed an anastomosis in this way. Following the anastomosis, the blood flow was observed. Thereafter, a pectoralis major flap (PM-flap) prepared. A skin island of the PM flap is attached to the remainder hypo pharynx and the base of the tongue for reconstruction. The patient had an uneventful recovery and the tongue remained viable in the follow-up period.

Discussion

Resection of the tongue is commonly performed due to malignant head and neck tumors. Reconstruction of this organ following surgical resection remains one of the most challenging conditions in head and neck oncology. Recent trends in tongue reconstruction have focused on optimizing its functions and maximizing the quality of life [4]. Despite several reconstructive techniques can restore the shape, and the volume of the tongue quite well, but their functional outcomes are still limited [5]. The tongue plays a critical role in speech, swallowing, taste, oral hygiene and airway protection. It must be preserved as much as possible and avoided an unnecessary resection. Preservation its function is important to maintain a good quality of life [1-2].

The blood supply of the tongue is derived from the lingual arteries. It originates from the external carotid artery and courses on the deep surface of the hyoglossus muscle. The deep lingual artery then branches into a dorsal lingual artery and the sublingual artery. The veins form venae comitantes and join into the facial vein or the internal jugular vein. Its neural stimulus comes from the hypoglossal nerve [2,6].

In the case we reported, the tumor put at risk of the arterial flow of the tongue. On the left side, a large segment of the lingual artery and the left hypoglossal nerve was surrounded by the tumor, resulted in both sectioned. On the right side, following a resection of 1 centimeter segment of the lingual artery, end to end anastomosis was performed successfully due to its voluted formation; otherwise, an interposition graft had to be required (Figure 1 A), [7]. The tongue has also an extensive arterial network between its right and left side; hence, one sided revascularization was enough to supply the entire tongue. In this way, we avoided the need to a flap reconstruction. This case represents one of the few reports of a successfully resulted micro vascular revascularization of the tongue

achieved by end-to-end anastomosis between the lingual artery remnants, after a tumor resection. There have been only 3 other reports of revascularization of the tongue secondary to tumor surgery in English literature.

A single case of direct anastomosis of the lingual to the facial artery following tongue base cancer resection was reported by Shemen et al. [3] in 1988. Three cases reported by Thoma et al. [7] in 2001. They used interposition vein grafts in one patient successfully. In the other two patients, they did a direct anastomosis between the lingual artery remnants similar to our case, but one of them resulted with failure. One year later in 2002, Cole and Evans [8] reported a radial forearm free flap technique for both reconstruct the oropharyngeal defect and restore the blood flow of the tongue as a bridge. The proximal end of the radial artery was anastomosed to the left external carotid artery, and the distal end anastomosed to the right lingual artery resulted in a successful perfusion. Additionally, in 1998 Buntic and Buncke [1] and in 2006 Egozi et al. [2] reported 2 cases microscopically replanted successfully after a total, and a near total traumatic tongue amputation.

In conclusion; tongue should be preserved as much as possible due to its crucial importance. Preserving the tongue is superior to any kind of reconstruction. In appropriate cases, microsurgical revascularization is an eligible option for this purpose.

References

1. Buntic RF, Buncke HJ. Successful replantation of an amputated tongue. *Plast Reconstr Surg.* 1998 May; 101(6):1604-7.
2. Egozi E, Faulkner B, Lin KY Successful revascularization following near-complete amputation of the tongue. *Ann Plast Surg.* 2006 Feb; 56(2):190-3.
3. Shemen L, Romita M, Godfrey P, Godfrey N, Hamburg R. Microvascular revascularization of the tongue. *J Reconstr Microsurg.* 1988 Jul; 4(4):267-9.
4. Bokhari WA, Wang SJ. Tongue reconstruction: recent advances. *Curr Opin Otolaryngol Head Neck Surg.* 2007 Aug; 15(4):202-7.
5. Leymarie N, Karsenti G, Sarfati B, Rimareix F, Kolb F. Modification of flap design for total mobile tongue reconstruction using a sensitive antero-lateral thigh flap. *J Plast Reconstr Aesthet Surg.* 2012 Jul; 65(7):e169-74.
6. Lopez R, Lauwers F, Paoli JR, Boutault F, Guitard J. Vascular territories of the tongue: anatomical study and clinical applications. *Surg Radiol Anat.* 2007 Apr; 29(3):239-44.
7. Thoma A, Ching S, Archibald S, Jackson S. Microsurgical tongue revascularization following oromandibular cancer resection. *Plast Reconstr Surg.* 2001 Jul; 108(1):141-4.
8. Cole RP, Evans DM. Tongue revascularization. *Plast Reconstr Surg.* 2002 May; 109(6):2164-5.