

**A RARE VARIANT OF LIPOMA: SIALOLIPOMA**

Head and Neck Surgery

Submitted : 05.10.2015

Accepted : 05.04.2016

Published : 05.04.2016

**Esin Kaymaz Gezer<sup>1</sup>, Didar Gürsoy<sup>2</sup> , Hakan Tekin<sup>1</sup>**<sup>1</sup> Van Bölge Eğitim ve Araştırma Hastanesi<sup>2</sup> Hatay Mustafa Kemal Üniversitesi Tıp Fakültesi Patoloji Anabilim Dalı**Özet****NADİR BİR LİPOM VARYANTI: SIALOLİPOM**

Bu olguda oldukça nadir görülen bir antite olan sialolipomu literatürler eşliğinde değerlendirildi. Son bir yıl içerisinde büyüme gösteren ağrısız, yanakta kitle şikayeti olan 49 yaşındaki kadın hastanın lezyonu eksize edildi. Mikroskopik inceleme sonucu olguya sialolipom tanısı kondu. Sialolipom diğer tükürük bezi tümörleri ile ayırıcı tanıda akılda tutulması gereken nadir bir lipom varyantıdır.

**Anahtar kelimeler:** Sialolipom, Tükürük Bezi tümörleri, Lipom

**Abstract****A RARE VARIANT OF LIPOMA: SIALOLIPOMA**

**Objective:** In this case we aimed to report a rare entity; sialolipoma and review the literature. **Case Report:** Here we report a 49 year old female presented with a painless, buccal mass, which had been growing slowly over one year. Lesion had been excised totally. According to microscopic examination; the diagnosis was sialolipoma. **Conclusion:** Sialolipoma is a rare variant of lipoma that should be kept in mind for differential diagnosis of salivary gland tumors.

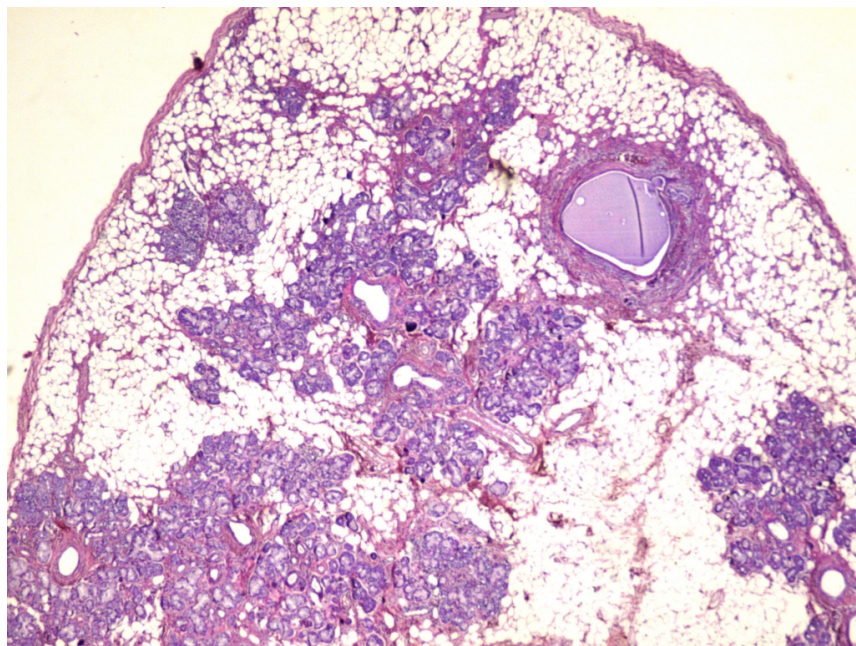
**Keywords:** Sialolipoma, Salivary Gland Tumors, Lipoma

**Introduction**

Sialolipoma is a rare variant of salivary gland tumor which is composed of mature adipocyte and glandular tissue. Initially it is identified by Nagoe and according to Nagoe et al sialolipoma is a lipomatous proliferation that consists of acinar and ductal structures bounded by a very thin fibrous tissue [1]. Although sialolipoma is usually located at parotid gland, it can be found in any oral or maxillofacial site [1-2]. It typically occurs at adults with a ratio 90% however; cases in infants have been reported [3]. Etiopathogenesis is not clear yet.

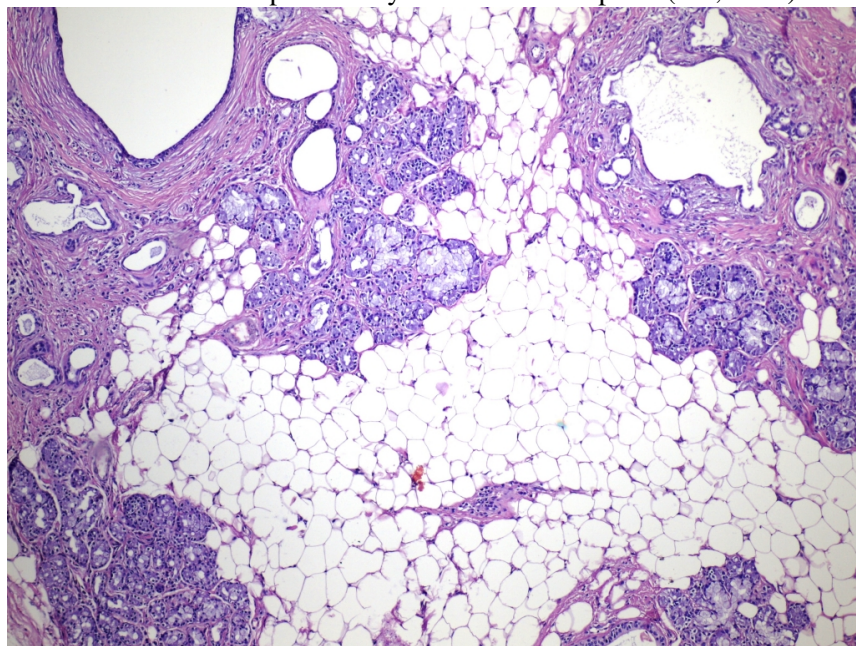
**Case Report**

A 49 year old female presented with a painless, buccal mass, which had been growing slowly over one year. There was no infection or injury in her medical history. Physical examination showed a 0.9 cm diameter palpable nontender, round, mobile and elastic mass in the patient's buccal mucosa. Ultrasonography (USG) showed that the mass was of a relatively heterogeneous, hypoechoic nature, with ill-defined margins. Lesion had been excised totally. Gross examination revealed that the tumor was 0.9x0.7x0.5 cm, well-circumscribed, soft, yellowish. Microscopic examination showed that the tumor was encapsulated by a thin fibrous capsule; the majority of the tumor consisted of adipocytes, and structures of salivary gland with an equal proportion (Figure 1, 2).



**Figure 1**

Tumor was encapsulated by a thin fibrous capsule (HE, x100)

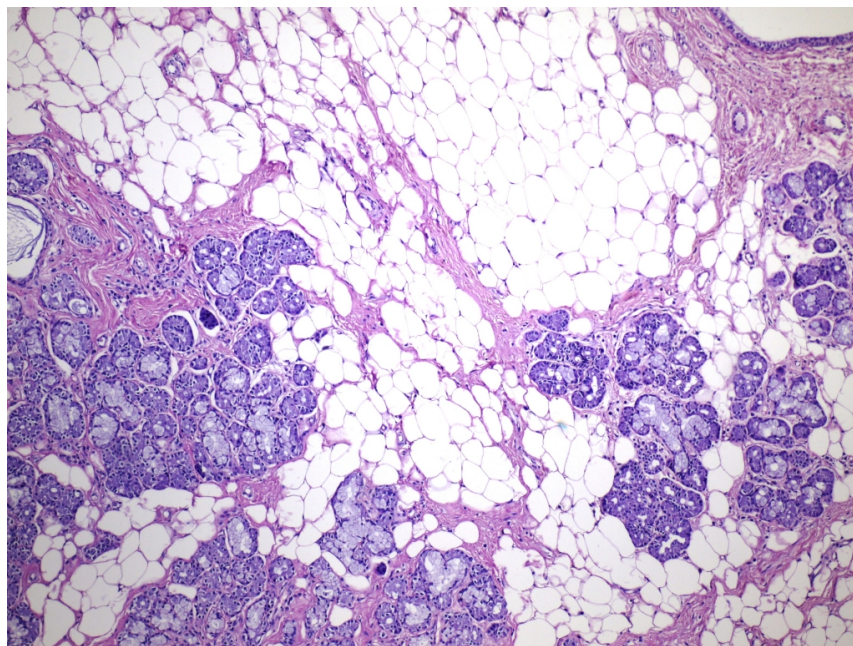


**Figure 2**

Tumor composed of adipocytes, and structures of salivary gland with an equal proportion (HE, x200)

There was no pleomorphism and mitotic activity (Figure 3).





**Figure 3**

There was no pleomorphism and mitotic activity (HE, x400)

These histopathologic findings supported a diagnosis of sialolipoma. No add-on therapy was applied to the patient.

## Discussion

Sialolipoma is a rare variant of mesenchymal neoplasms of salivary gland with a ratio 0.3% [4]. To our knowledge 36 cases of sialolipoma have been reported in the English literature and 18 of them were located in minor salivary glands [5]. It was first described by Nagao et al., in 2001 [1].

Although no preference for an anatomic site has been described for sialolipomas, the most common site is the parotid gland [1-2]. Also cases in minor salivary gland, buccal mucosa, palate, tongue and lower lip have been reported [6].

Clinically, sialolipomas usually present as a solitary painless palpable mass. Females are affected slightly more than males [6]. While sialolipomas of major salivary glands were reported both in adults and pediatric cases, minor salivary gland tumors were reported in adults only [7]. Generally, sialolipoma appears as a well-circumscribed lesion during high-resolution CT or a high-intensity MRI. Although there is no distinguishable radiographic sign for sialolipoma compared to a typical fatty lesion in the head and neck region [8-9]. Fine needle aspiration cytology may be useful for diagnosis of lipomatous tumors of the salivary gland but definitive diagnosis of sialolipoma is based on histopathologic features [10].

Histological findings of haematoxylin and eosin staining are; a well circumscribed mass composed of benign, mature, neoplastic adipose elements mixed with scattered foci of nonneoplastic, atrophic salivary gland tissues, often surrounded by a delicate fibrous tissue [6]. Adipose tissue constitutes 90% of parotid gland sialolipomas and 50% of palate cases [11]. In our case on histologic evaluation there was mature adipocytic tissue and atrophic salivary gland ductus with an equal proportion. Ductal dilation, hyperplasia, oncocytic changes and sebaceous and squamous ductal metaplasia can be seen in ductal component. In some cases fibrosis, basophilic amorphous materials with mucin and myxoid islands are also present [2,6,11]. Myxoid degeneration was observed only in

minor salivary gland tumors whereas nerve entrapment was noted only in major salivary glands [7]. Additionally, lymphocytic infiltration and enlarged congested vessels are reported. There is no mitotic activity or pleomorphism in neither adipocytes nor acinar and ductal cells [6].

The differential diagnosis of sialolipoma includes lesions with extensive adipose tissue, such as lipomatosis, pleomorphic adenoma with extensive adipose content and adenolipoma [11]. CT or MRI can be helpful in the differential diagnosis [7]. Lipomatosis is nonmalignant overgrowth of adipose tissue throughout the salivary gland paranchyma and it generally occurs in elderly patients. Lipomatosis can be excluded from sialolipoma by lacking of the fibrous capsule. In addition lipomatosis is associated with some medical condition such as diabetes mellitus, malnutrition, chronic alcoholism and liver cirrhosis. Differentiation pleomorphic adenoma from sialolipoma is based on presence of ducts and strands of dark-staining myoepithelial cells [6,11]. Lipoma has no salivary gland elements entrapped in adipose tissue [2]. Adenolipoma has histologic features similar to sialolipoma; but it is composed of adipocytes and ductal structures without acinar cells [6,10]. If glandular component has oncocyctic changes, it should be differentiated from oncocytoma [10].

Although the histopathogenesis of sialolipoma is not clear, it is believed that sialolipoma may be associated with salivary gland dysfunction, which results in salivary gland alterations rather than representing a neoplastic process [3,5,7,11] This hypothesis is favored microscopically by replacement of the normal salivary gland tissue with mature adipose tissue admixed with atrophic salivary glandular elements [6,11].

According to literature none of the cases of sialolipoma showed recurrences except for one case by Lee et al. Lee et al suggested that this recurrence may be due to a novel and independent focus because of the clear safety margin of the first surgical specimen [8]. Malignant transformation of sialolipoma has not been reported yet [6].

Treatment of sialolipoma in the minor salivary gland is complete surgical excision of the tumor whereas treatment of tumors in parotid glands is superficial parotidectomy with preservation of facial nerve [2,6]. A complete parotidectomy with preservation of the facial nerve has been reported in two cases [6].

## Conclusion

In conclusion; sialolipoma is a very rare salivary gland neoplasm which occurs predominantly in parotid gland and also can be seen in minor salivary gland. In addition it is important to differentiate sialolipoma from other salivary gland neoplasms. Postoperative follow-up is considered for multifocal lesions which could result in recurrence whether a successful surgical examination with clear safety margins.

## References

1. Nagao T, et al. A report of seven cases of a new variant of salivary gland lipoma. *Histopathology* 2001;38(1):30-6.
2. Lin Y, et al. Sialolipoma of the floor of the mouth: a case report. *Kaohsiung J Med Sci.* 2004;20:410-4.
3. Nonaka CF, et al. Sialolipoma of minor salivary glands. *Ann Diagn Pathol.*2011;15:6-11.
4. Gnepp DR et al. *Diagnostic Surgical Pathology of the Head and Neck.* 2nd edition. Salivary and Lacrimal Glands. Philadelphia; 2009. 525-26.
5. Khazaeni K, et al. Sialolipoma of salivary glands: Two case reports and review of the literature. *Dent Res J (Isfahan).* 2013;10(1):93-7.
6. Binmadi NO, et al. Sialolipoma of the Lower Lip: Case Report and Literature Review. *The Open Dentistry Journal.* 2012; 6:208-211.
7. Qayyum S, et al. Sialolipoma of the parotid gland: Case report with literature review comparing major and minor salivary gland sialolipomas. *J Oral Maxillofac Pathol.* 2013;17(1):95-7.

8. Lee PH, Chen JJ, Tsou YA. A recurrent sialolipoma of the parotid gland: A case report. *Oncol Lett.* 2014;7(6):1981-1983
9. Doğan S, et al, Samim EE. Sialolipoma of the parotid gland. *J Craniofac Surg* 2009; 20(3):847-8.
10. Ahn D, et al. Oncocytic Sialolipoma of the Submandibular Gland. *Clinical and Experimental Otorhinolaryngology.*2014; 7(2):149-152.
11. Moraes M, et al. Sialolipoma in Minor Salivary Gland: Case Report and Review of the Literature. *Head and Neck Pathol.* 2010; 4:249-52.
12. Akrish S, et al. Sialolipoma of the salivary gland: Two new cases, literature review, and histogenetic hypothesis. *J Oral Maxillofac Surg.* 2011;69:1380–4.

### **Information About Previous Presentations**

This case will be presented as a case report in 25th National Pathology and 6th Cytopathology Congress, in 14-17 October 2015 at Bursa, Turkey