

A CERVICAL BRONCHOGENIC CYST MIMICKING PERITHYROIDAL CYST

Head and Neck Surgery

Submitted : 07.12.2015

Accepted : 18.12.2015

Published : 18.12.2015

Cem Bayraktar¹, Abbas Ali Tam¹, Sedat Doğan¹, Mehmet Karataş¹, Ruslan Abdullayev¹, İbrahim Halil Erdoğan¹

¹ Adıyaman Üniversitesi Tıp Fakültesi

Özet

PERİTİROİDAL KİSTİ TAKLİT EDEN BİR SERVİKAL BRONKOJENİK KİST

Bronkojenik kistler embriyogenez esnasında trakeobronşiyal ağacın anormal tomurcuklanmasına bağlı gelişir. Bu kistler en sık mediastende görülür ve seyrek olarak servikal bölgede ortaya çıkar. Hastalar genellikle asemptomatiktir ancak kistin komşu yapılara baskısı veya enfekte olması sonucu hastalarda stridor, ağrı, öksürük veya dispne ortaya çıkabilir. Burada 47 yaşında kadın hasta endokrinoloji uzmanı tarafından boğaz ağrısı ve tiroidal bölgede ağrı nedeniyle kliniğimize konsülte edildi.

Anahtar kelimeler: Bronkojenik kist, Kistik kitle, Boyun, Peritiroidal kitle

Abstract

A CERVICAL BRONCHOGENIC CYST MIMICKING PERITHYROIDAL CYST

Bronchogenic cysts are originated from the abnormal budding of the tracheobronchial tree during embryogenesis. These are cysts that seen in mediastinum mostly and appear in cervical region rarely. Patients are usually asymptomatic but when the cyst compresses adjacent structures or is infected, they may present with stridor, pain, cough, or dyspnea. Herein, a 47 year-old woman with sore throat and pain at thyroidal region who was referred by the endocrinologist to our clinic is presented.

Keywords: Bronchogenic cyst, Cystic mass, Neck, Perithyroidal mass

Introduction

It is believed that bronchogenic cyst (BC), a rare congenital anomaly, results from abnormal budding of the ventral foregut which constitutes tracheobronchial tree later on [1-5]. It's commonly seen in mediastinum and pulmonary parenchyma, but neck is a relatively unusual site for BCs [1,6,7]. Majority of BCs are diagnosed in pediatric age group [2,4]. Patients are usually asymptomatic. However, as the cyst compresses adjacent structures or is infected, they may present with stridor, pain, cough, or dyspnea [6]. Most of BCs are incidentally detected on radiographs [1,7]. Uniloculation and liquid fluid are frequently-encountered features of these cysts but hemorrhagic liquid or air may also be seen [4]. Herein we present a bronchogenic cyst that appears as perithyroidal cyst.

Case Report

A 47 year-old woman with sore throat and pain at thyroidal region was referred by the endocrinologist to our clinic. Physical exam showed no any palpable neck mass. Ultrasonography revealed a 17x11 mm, heterogen cystic mass with multipl calcification in right infrahyoideal area (Figure 1).

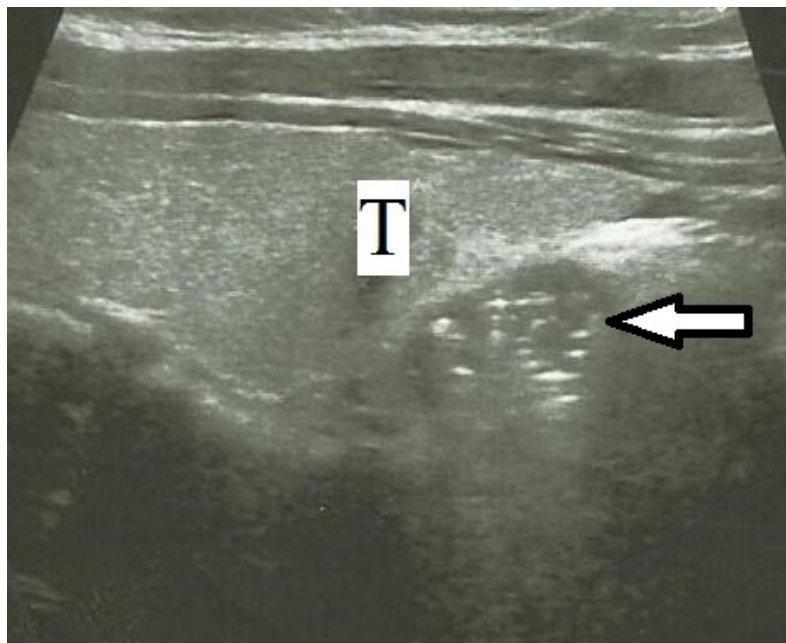


Figure 1

Ultrasonographic image of heterogen cystic mass with multiple calcifications in the neighbourhood of trachea at the inferior of the right thyroid lobe (17.9 x 11.3 mm, T: right thyroid lobe, arrow: mass)

Her thyroid function tests (Thyroid-Stimulating Hormone, free T3 and free T4), calcium and parathormone levels were in normal range. Fine needle aspiration did not give a definite diagnosis. Neck exploration was planned. First of all, right hemithyroidectomy was performed, then recurrent nerve and parathyroid glands were identified. A 2 cm-cystic mass tightly adherent to trachea and esophagus was inbetween right recurrent nerve and trachea, excised with meticulous dissection and the site of origin was sutured (Figure 2-3).

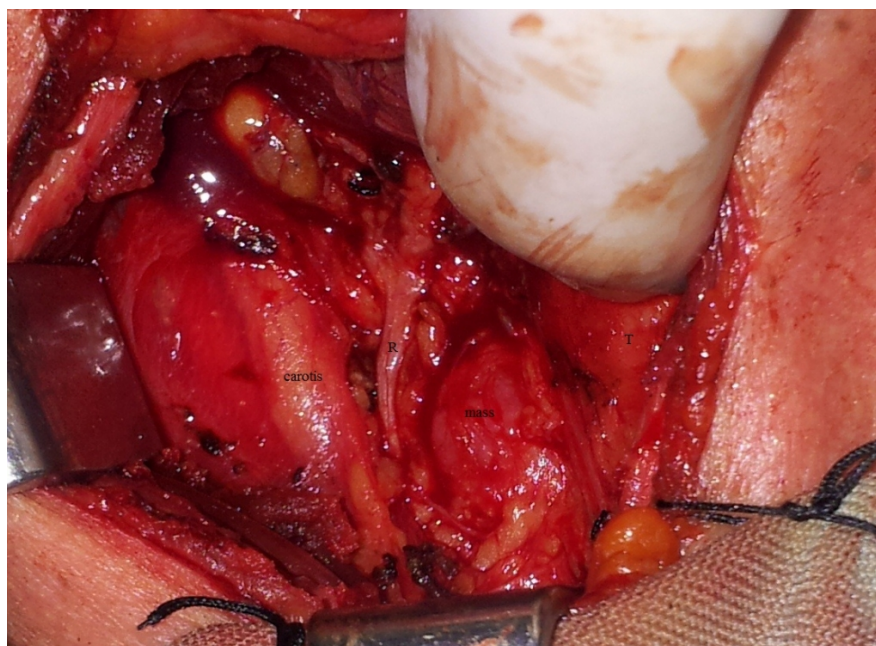


Figure 2

Mass lying between right recurrent nerve and trachea (R: right recurrent laryngeal nerve, T: trachea)

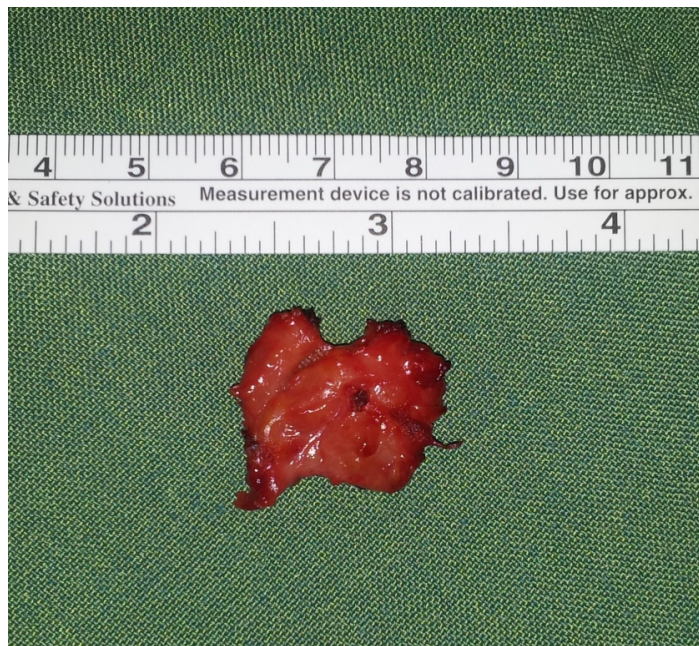

Figure 3
Excised reddish mass about 2 cm diameter

Pseudostratified ciliated columnar epithelium fitted multiple cystic spaces on histopathologic examination, pointed as bronchogenic cyst (Figure 4). Postoperative recovery was uneventful and no recurrence was observed at sixth month.

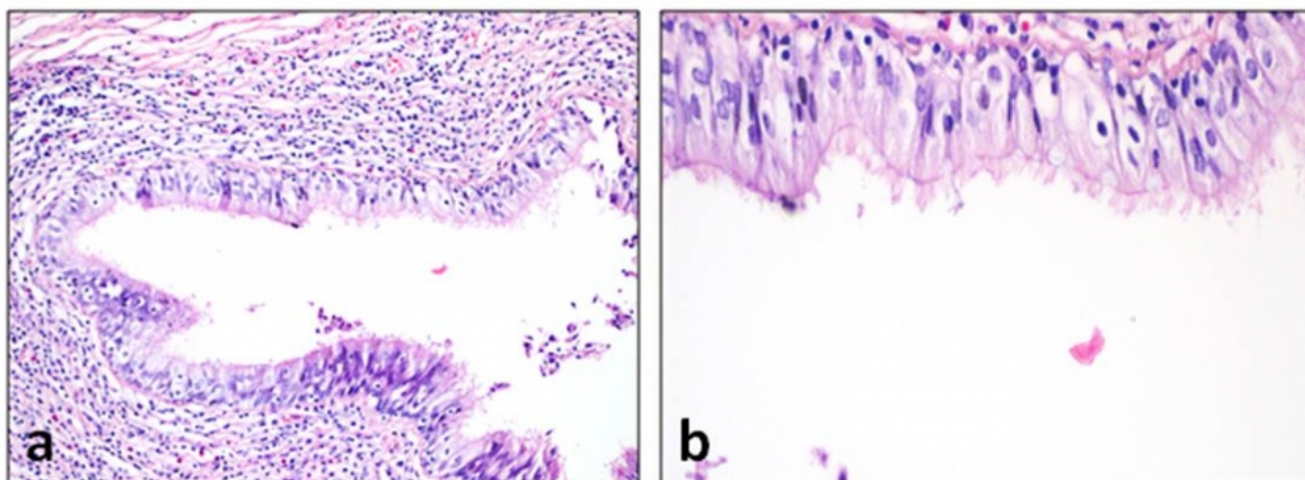


Figure 4
a) Cystic space lined with pseudostratified ciliated columnar epithelium (H&E X 10) b) Ciliated cells at columnar epithelium (H&E X 40)

Discussion

BCs are rare, benign, congenital lesions and although its more common in children, they can be seen in adult age [4]. Primitive foregut divides to form the ventral trachea and dorsal esophagus during fourth-fifth week of

embryologic development. As a result of abnormal budding of the ventral foregut, BC occurs (8). Buds can migrate abnormally during development and appear intrathoracic or extrathoracic regions such as abdomen, retroperitoneal, subcutis or neck [4,8].

Maier (9) classified BCs into five groups according to their site of origin; paratracheal, carinal, hilar, paraesophageal and atypic. We met only three cases which limited to the tracheo-esophageal groove in the literature; Bocciolini et al. [4], Sanli et al. (10) and Al-kasspooles et al. [11] presented 57 year-old man with right sided 5x4 cm, 48 year-old woman with right sided 3x2 cm and 62 year-old man with 7x4 cm bronchogenic cysts respectively.

Definitive diagnosis can only be made with histopathologic evaluation [1,7]. Cyst epithelium is pseudostratified ciliated columnar epithelium and may contain goblet cells. Sometimes squamous epithelium can be seen secondary to infections [4]. Histologically cyst wall may include smooth muscles, mucous glands and cartilage like in bronchus [1].

In the differential diagnosis of the cystic neck masses, branchial cleft cysts, thyroglossal duct cysts, parathyroid cysts, cervical thymic cysts, cystic hygromas, and cystic neuromas should be kept in mind [1,5,6]. Localization and histology are very important for determining these lesions [2,4].

The patient was consulted to our clinic with suspicion of carcinoma at parathyroid area because of multiple calcifications in the mass. Majority of the parathyroid carcinomas are functional and high levels of both parathormone and calcium are encountered at laboratory tests [12]. On the other hand, another type of those tumors is non-functional type and together with normal laboratory findings. Usually parathyroid carcinomas are solid lesions and seem as adenomas [13]. A parathyroid carcinoma emerged as a cystic neck mass was reported by Pirundini et al [14]. In our case, there was a cystic mass at parathyroid region with normal calcium and parathormone levels, so we think that carcinoma is a conceivable prediagnosis. Another misdiagnostic factor was sonographic multiple calcified content of the mass which led us to suspect malignancy. But BC's calcific densities are known and it's thought that high calcium content cause these lesions [15].

Definitive treatment for BCs is complete surgical removal [1,3,5] but there is no need for wide resection [7]. In some cases, carcinoma were reported on the ground of these cysts in the literature. Tanaka et al. (16) reported mucoepidermoid carcinoma which originated from thymic bronchogenic cyst in a 59 year-old woman and Tanita et al. [17] informed malign melanoma case arising from a scapular cutaneous BC in a 46 year-old man. We believe that these congenital cysts have to be excised when they are encountered because of their malign potential.

In conclusion, in the differential diagnosis of cystic neck masses, BCs must be kept in mind and complete resection of these lesions should be performed because of their malign potential.

References

1. Min KW, Jang SH, Song YS, Cho SH, Chon SH, Paik SS. An unusual case of bronchogenic cyst mimicking thyroid cystic tumor. *Otolaryngol Head Neck Surg.* 2007;137:520-1. Medline: 17765791
2. Newkirk KA, Tassler AB, Krowiak EJ, Deeb ZE. Bronchogenic cysts of the neck in adults. *Ann Otol Rhinol Laryngol.* 2004;113:691-5. Medline: 15453524
3. Moz U, Gamba P, Pignatelli U, D'Addazio G, Zorzi F, Fiaccavento S, et al. Bronchogenic cysts of the neck: a rare localization and review of the literature. *Acta Otorhinolaryngol Ital.* 2009;29:36-40. Medline: 19609381
4. Bocciolini C, Dall'olio D, Cunsolo E, Latini G, Gradoni P, Laudadio P. Cervical bronchogenic cyst: asymptomatic neck mass in an adult male. *Acta Otolaryngol.* 2006;126:553-6. Medline: 16698709

5. Ustundag E, Iseri M, Keskin G, Yayla B, Muezzinoglu B. Cervical bronchogenic cysts in head and neck region: review of the literature. *J Laryngol Otol.* 2005;119:419-23. Medline: 15992465
6. Annamalai A, Shemen L, Ruiz D. An unexpected finding of a bronchogenic cyst presenting as a thyroid mass. *Head Neck Pathol* 2011;5:416-8. Medline: 21681663
7. Shimizu J, Kawaura Y, Tatsuzawa Y, Maeda K, Suzuki S. Cervical bronchogenic cyst that presented as a thyroid cyst. *Eur J Surg.* 2000;166:659–61. Medline: 11003438
8. Hadi UM, Jammal HN, Hamdan AL, Saad AM, Zaatari GS. Lateral cervical bronchogenic cyst: an unusual cause of a lump in the neck. *Head Neck.* 2001;23:590-3. Medline: 11400248
9. Maier HC. Bronchogenic cysts of the mediastinum. *Ann Surg.* 1948;127:476-/502. Medline: 17859095
10. Sanli A, Onen A, Ceylan E, Yilmaz E, Silistreli E, Açıkel U. A case of a bronchogenic cyst in a rare location. *Ann Thorac Surg.* 2004;77:1093-4. Medline: 14992942
11. Al-kasspooles MF, Alberico RA, Douglas WG, Litwin AM, Wiseman SM, Rigual NR, et al. Bronchogenic cyst presenting as a symptomatic neck mass in an adult: case report and review of the literature. *Laryngoscope.*2004;114:2214-7. Medline: 15564848
12. Schoretsanitis G, Daskalakis M, Melissas J, Tsiftsis DD. Parathyroid carcinoma: clinical presentation and management. *Am J Otolaryngol.* 2009;30:277-80. Medline: 19563942
13. Kassahun WT, Jonas S. Focus on parathyroid carcinoma. *Int J Surg.* 2011;9:13-19. Medline: 20887820
14. Pirundini P, Zarif A, Wihbey JG. A rare manifestation of parathyroid carcinoma presenting as a cystic neck mass. *Conn Med.* 1998;62:195-7. Medline: 9611414
15. Nakata H, Sato Y, Nakayama T, Yoshimatsu H, Kobayashi T. Bronchogenic cyst with high CT number: analysis contents. *J Comput Assist Tomogr.* 1986;10:360-2. Medline: 3950171
16. Tanaka M, Shimokawa R, Matsubara O, Aoki N, Kamiyama R, Kasuga T, et al. Mucoepidermoid carcinoma of the thymic region. *Acta Pathol Jpn.* 1982;32:703-12. Medline: 7113703
17. Tanita M, Kikuchi-Numagami K, Ogoshi K, Suzuki T, Tabata N, Kudoh K, et al. Malignant melanoma arising from cutaneous bronchogenic cyst of the scapular area. *J Am Acad Dermatol.* 2002;46:19-21. Medline: 11807461

Information About Previous Presentations

This case report was presented as poster presentation at 36. Turkish National Congress of ENT and Head-Neck Surgery in Antalya/Turkey, in 2014.