

AN UNUSUAL ENCOUNTER: ISOLATED LINGUAL NEUROFİBROMA

Head and Neck Surgery

Submitted : 25.03.2020

Accepted : 07.04.2020

Published : 07.04.2020

Furkan Şan¹, Onur Nursaçan², Mustafa Kesler¹¹ Sivas Numune Hastanesi² Erciyes Üniversitesi Tıp Fakültesi**Özet****İZOLE LİNGUAL NÖROFİBROM: NADİR BİR VAKA**

Nörofibromlar sinir kaynaklı tümörlerdir ve sıklıkla Von-Recklinghausen sendromu (VRS) olarak da bilinen nörofibromatozis tip 1 hastalığı ile birlikte görülürler. VRS, cilt nörofibromları, cafe-o-lait lekeleri, gözde Lisch nodülleri ve optik gliomlar gibi bir çok sistemik anomalinin görüldüğü nörokutanöz bir sistemik hastalıktır. VRS'li hastaların %4-7'sinde oral tutulum görülmeyle birlikte, VRS'ye ait hiç bir başka bir tutulum olmadan, oral kavitede izole olarak görülen nörofibrom çok nadir bir durumdur. Bu hastalar, nörolojik, oftalmolojik ve dermatolojik olarak VRS'nin diğer tutulumları açısından muayene edilmelidir. Nörofibromların optimal tedavisi, kitlenin tam eksizyonu ile olur; buna rağmen nüks açısından hastalar cerrahi sonrası takip edilmelidirler. Bu çalışmada, dilin lateral kısmında saptanan ve total eksizyon ile başarılı bir şekilde tedavi edilen izole nörofibrom vakası tartışılacaktır.

Anahtar kelimeler: izole, oral kavite, nörofibrom, lingual

Abstract**AN UNUSUAL ENCOUNTER: ISOLATED LINGUAL NEUROFİBROMA**

Neurofibromas are nerve originated tumors, commonly seen with neurofibromatosis type 1, also known as Von-Recklinghausen syndrome (VRS). VRS is a neurocutaneous systemic disease with a myriad of systemic anomalies, such as cutaneous neurofibromas, café-au-lait spots, Lisch nodules, optic gliomas. Although oral cavity is involved 4-7% of patients with VRS; isolated neurofibroma in oral cavity without any other symptom of VRS is certainly a rare presentation of this disease. Such patients should be evaluated neurologically, ophthalmologically and dermatologically for other manifestations of VRS. For neurofibromas, total excision is a must for optimal treatment, yet follow-up is also needed after surgery for recurrences. We present you a patient with an isolated neurofibroma on the lateral border of the tongue, successfully treated with complete surgical excision.

Keywords: isolated, oral cavity, neurofibroma, lingual

Introduction

Neurofibromas are nerve originated tumors, commonly seen with neurofibromatosis type 1, also known as Von-Recklinghausen syndrome (VRS). VRS is a neurocutaneous systemic disease with autosomal dominant transmission with variable penetrance and expressivity[1]. VRS is characterized by cutaneous neurofibromas, café-au-lait spots, Lisch nodules, optic gliomas and multiple other systemic anomalies[2]. Only 4-7% of patients with VRS has oral manifestations; but isolated neurofibroma in oral cavity without any other symptom of VRS is certainly a rare presentation of this disease[3]. Being an uncommon entity, we present you a patient with an isolated neurofibroma at the lateral border of the tongue, treated with complete surgical excision.

Case Report

Corresponding Author: Furkan Şan, Sivas Numune Hastanesi Kardesler mah. 51-52 sk. Sivas Modern Sitesi C Blok No:5/2
Daire:25
furkansan@gmail.com

Şan F, Nursaçan O, Kesler M. İzole lingual nörofibrom: nadir bir vaka. ENTcase. 2020;6(2):21-26

A 64-year old female patient without any significant medical history applied to our clinic with a painless mass located at the left lateral border of her tongue for six months. The mass was described by patient as a slowly but gradually growing tumor, causing stiffness, decrease in the quality of voice and difficulty in mastication. Oral examination revealed a 15 x 15 mm, semielastic and semi-mobile mass at the left lateral border of the tongue, covered with nonulcerated lingual mucosa.

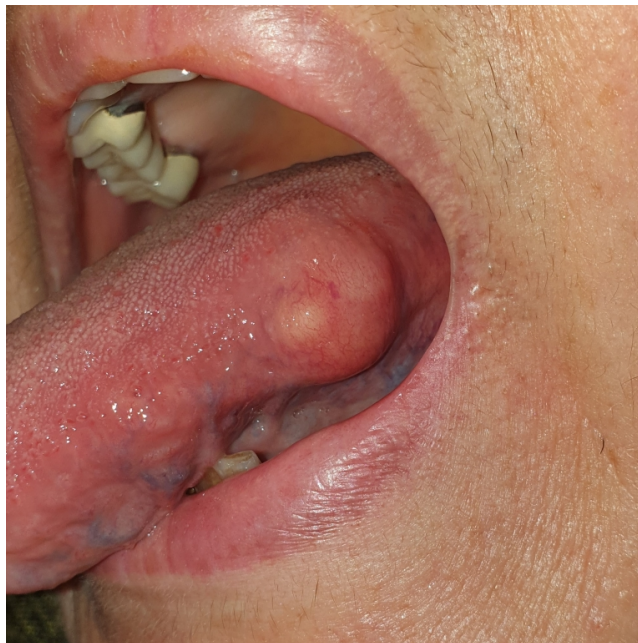

Figure 1

The mass on the left lateral border of the tongue

Mass was nonreducible, nontender and nonpulsatile with palpation. Being just beneath the lingual mucosa and small in size, borders of the mass was easily seen; thus no radiologic examination was done. Routine laboratory tests were within normal limits.

The patient underwent total surgical excision of the mass with infiltration anesthesia using lidocaine with adrenaline. A horizontal incision was performed on lingual mucosa, just above center of the mass. Mucosal flaps were elevated in superior and inferior sides to reveal the perimeter of the mass. Separation of mass from the lingual muscle tissues were relatively easy, neither a significant vascular structure nor a nerve trunk were encountered. After total excision of the mass, 4/0 Vicryl sutures were used for mucosal closure on the incision. Sensory and motor functions of the tongue is preserved and there were no complications in post-operative period.

Macroscopic examination showed a well-demarcated, non-capsulated, whitish gray, elastic and solid neoplasm.

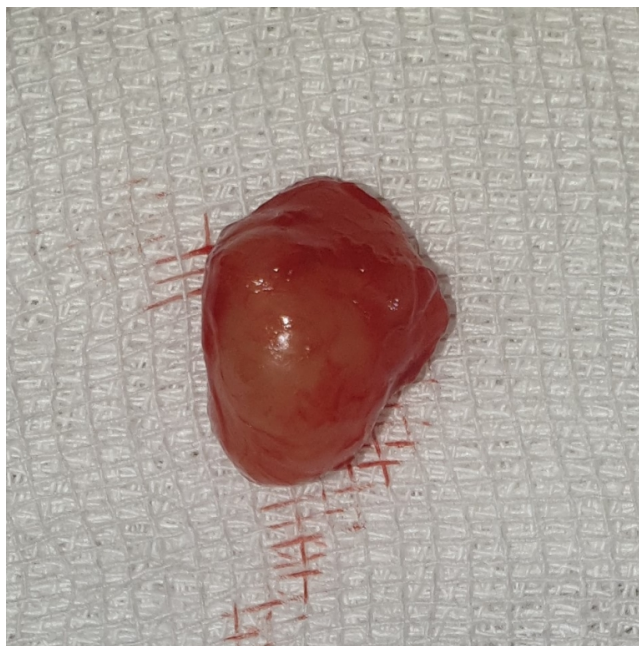

Figure 2

Well-demarcated, non-capsulated, whitish gray, elastic and solid tumor after removal

Histopathologically, tumor was well circumscribed with no distinct capsule.

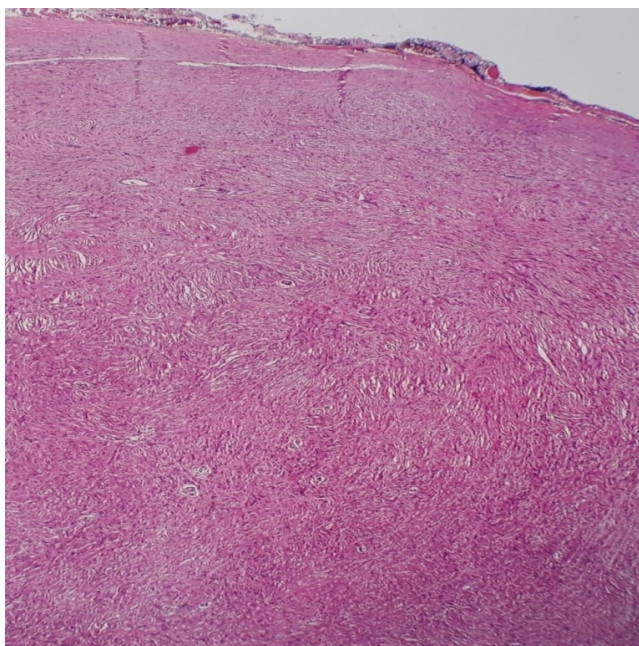


Figure 3

Well circumscribed tumor with no distinct capsule (H&E, original magnification x40)

There were scattered spindle cells with wavy cytoplasm and nucleus pattern, originating from peripheral nerve sheath.

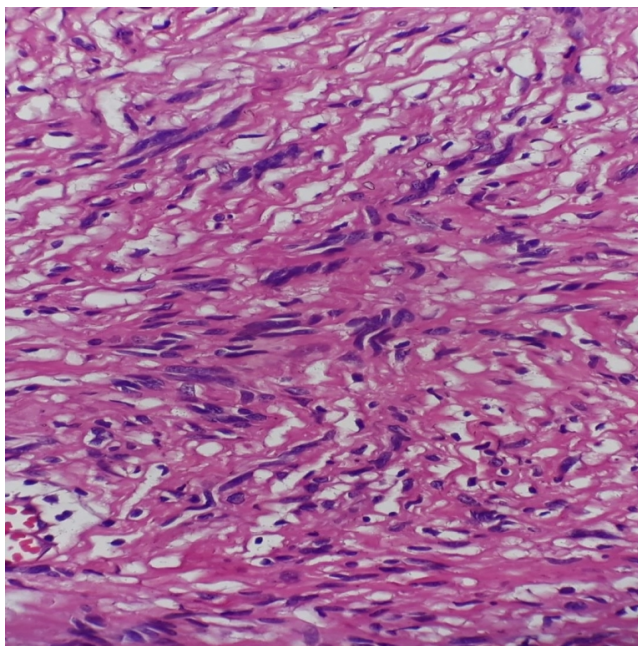


Figure 4

Scattered spindle cells with wavy cytoplasm and nucleus pattern, originating from peripheral nerve sheath (H&E, original magnification x400)

There were no Verocay bodies or Antoni areas. Most of the neoplastic cells were strongly positive for S-100 protein with immunohistochemical stain.




Figure 5

S-100 positive staining (IHC, original magnification x100)

Patient was systemically evaluated for VRS. Brain magnetic resonance imaging of the patient was existed from previous applications and there were no anomalies present. There was no café-au-lait spots on skin. No Lisch nodules were spotted on ophthalmologic examination. Pure tone audiometry test revealed a mild hearing loss on high frequencies in both ears; as expected with our patients age. Patient was followed up for six months with no sign of recurrence or any other symptom of VRS.

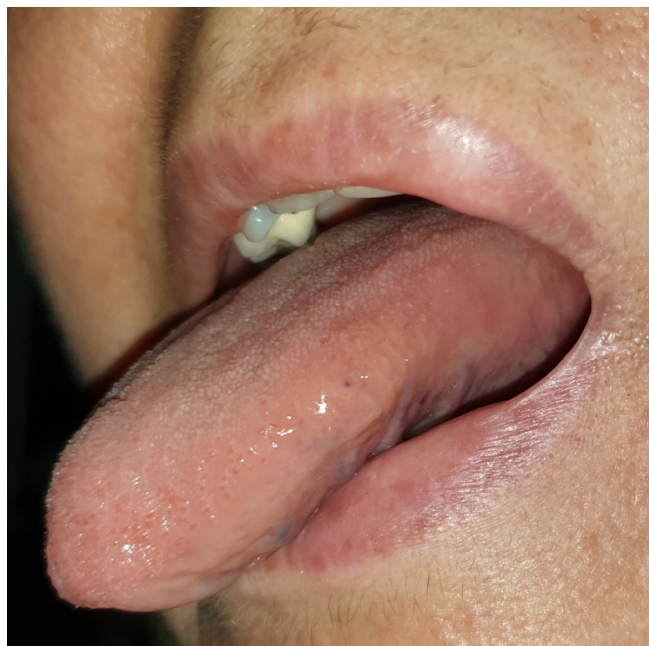

Figure 6

Patient after one year of follow-up with no recurrence

Discussion

Neurofibromatosis (NF) is a neurocutaneous syndrome with a broad spectrum and a myriad of symptoms. As it is well known, there are genetical and clinical individual variants of NF. Neurofibromatosis type 1, also known as Von Recklinghausen syndrome (VRS), is the most common form with an incidence of 1 in 3000[3] and have a autosomal dominant inheritance pattern. Neurofibromatosis type 2 has mostly central nervous system involvement and bilateral vestibular schwannoma is the characteristic feature of this form. Apart from these common forms of NF, there are also six more disease forms with various symptoms and clinical course[4].

Neurofibromas are nonencapsulated and benign neoplasms derived from a mixture of perineural fibroblasts and Schwann cells[5] and appear as soft and doughy masses[6]. Neurofibromas are generally associated with VRS and encountered as multiple lesions[6]. Neural sheath tumors are commonly seen in head and neck region, but oral manifestation of VRS is only %4-7[3]. Neurofibromas are generally seen as multiple masses, thus solitary neurofibromas like in our case are a rare entity. Whole body, especially upper airway must be examined for other undiagnosed neurofibromas.

Schwannoma, lymphoma, hemangioma, lipoma, granular cell tumors, rhabdomyosarcoma, benign and malignant tumors of minor salivary gland origin, and metastatic disease should be kept in mind for differential diagnosis of tongue masses[7]. Treatment for benign masses is generally surgical and diagnosis is generally confirmed after histopathologic examination. For malign masses, such as rhabdomyosarcoma, fine needle aspiration or incisional biopsies could light clinician's way for diagnosis. If there's doubt of character of mass, physical examination and radiologic imagings may be helpful for distinguishing malign masses from benign ones.

It is known that neurofibromas could be highly vascular masses and surgery may be hard due to excessive bleeding. Mass of our patient was just underneath the mucosa and total extirpation of mass was untroublesome. Especially for more deeper located lesions, surgeon should make effort not to make any lingual nerve injury.

In conclusion, neurofibromas are nerve originated tumors commonly seen with VRS. Isolated lingual neurofibroma is a rare entity and can be treated with a total excision. Such patients should be evaluated neurologically,

ophthalmologically and dermatologically for other manifestations of VRS, such as central nervous system tumors, Lisch nodules and cafe-o-lait spots; and need follow-up after surgery for recurrences.

References

1. Sharma SC, Srinivasan S. Isolated plexiform neurofibroma of tongue and oropharynx: a rare manifestation of von Recklinghausen's disease. *Journal of Otolaryngology-Head & Neck Surgery*, 1998;27(2):81.
2. Riccardi VM. von Recklinghausen neurofibromatosis. *New England Journal of Medicine*, 1981; 305(27):1617-1627.
3. Shapiro SD et al. Neurofibromatosis: oral and radiographic manifestations. *Oral Surgery, Oral Medicine, Oral Pathology*, 1984;58(4):493-498.
4. Sahota JS et al. Giant neurofibroma of the tongue. *International journal of pediatric otorhinolaryngology*. 1996;34(1-2):153-157.
5. Flint PW et al. *Cummings Otolaryngology-Head and Neck Surgery E-Book: Head and Neck Surgery, 3-Volume Set*. Elsevier Health Sciences; 2010.
6. Guneri E et al. Plexiform Neurofibroma of Tongue: A Case Report of a Child. *Turkish Journal of Pediatrics*. 2006;48(2):155.
7. Uzochukwu N, Shrier D, Lapoint R. Clear cell carcinoma of the base of the tongue: MR imaging findings. *American journal of neuroradiology*. 2007; 28(1):127-128.