

AN UNUSUAL REASON FOR CONDUCTIVE HEARING LOSS: PETRIFIED AURICLE

Otology

Submitted : 02.10.2019

Accepted : 18.05.2020

Published : 18.05.2020

Emine Demir¹, Özlem Çelebi Erdivanlı¹, Engin Dursun¹¹ Recep Tayyip Erdogan Üniversitesi Tıp Fakültesi

Özet

İLETİM TİPİ İŞİTME KAYBININ SIRA DIŞI NEDENİ: TAŞLAŞMIŞ KULAK

Dış kulağın genellikle kısmen, ender olarak ise total ossifikasyon veya kalsifikasyonu taşlaşmış kulak olarak isimlendirilir. Travma başta olmak üzere hipotermi, enfeksiyon ve çeşitli metabolik hastalıklar etyolojide suçlansa da kesin nedeni ortaya konulamamıştır. Genellikle asemptomatiktir, nadiren ağrı ve hassasiyete, nadiren de işitme kaybına neden olabilir. Bu yazıda, 22 yaşında bilateral işitme kaybı yakınmasıyla kliniğimize başvuran bayan hastayı sunduk. Hastanın tanısı fizik muayene ve temporal kemik bilgisayarlı tomografi ile konuldu. Taşlaşmış kulak ender görülür, semptomatik vaka sayısı ise oldukça azdır. Bu vakayla birlikte, literatür eşliğinde oldukça ender görülen işitme kaybı yapan taşlaşmış kulağı gözden geçirmeyi planladık.

Anahtar kelimeler: İşitme kaybı, taşlaşmış kulak, kulak kepçesi kemikleşmesi, kulak kepçesi kireçleşmesi

Abstract

AN UNUSUAL REASON FOR CONDUCTIVE HEARING LOSS: PETRIFIED AURICLE

Partial or rarely complete ossification or calcification of the outer ear is called the petrified auricle. Although the exact etiology is unknown; trauma, hypothermia, infection and various metabolic disorders could be the trigger. A petrified auricle is usually asymptomatic, but it can also cause pain, tenderness and rarely hearing loss. This article presents the case of a 22 year old woman who applied to our clinic with the complaint of bilateral hearing loss. The diagnosis was made with physical examination and temporal bone computer tomography. When we look at the literature, petrified auricle is rarely observed. As well as no cases of primary presentation with hearing loss. This case with petrified auricle in a patient with hearing loss.

Keywords: Hearing loss, petrified auricle, auricle ossification, auricle calcification

Introduction

The calcification or ossification of the cartilaginous parts of the outer ear is called a petrified auricle. It was first defined by Bochdalek in 1866.[1] The number of reported cases in the literature is really low and most of these are case reports. Petrified auricle could be unilateral or bilateral. Although the etiology is unknown, any metabolic or metastatic diseases, trauma, or infection which causes precipitation of calcium and phosphorus at the outer ear could be the reason.[2] The most commonly seen predisposing factor is local trauma.[3] This article presents a case of a female who presented with the complaint of hearing loss and aims to review the topic petrified auricle, a rarely reported disorder in the literature.

Case Report

A 22-year-old female patient presented to our clinic in November 2017 with the complaint of bilateral hearing loss. Also she reported that both of her auricles were tough and tender with any contact. There was no history of trauma, infection, or any chronic illness and the patient reported that she has these complaints since childhood.

In physical examination, auricles and the skin covering the ear lobule and auricle were bilaterally normal. Auricles were rigid and tender with palpation but the auricular lobule was soft. The otoscopic examination could not be completed due to the pain and lack of flexibility of the outer ear.

Audiometric examination revealed bilateral moderate conductive type hearing loss (Figure 1).

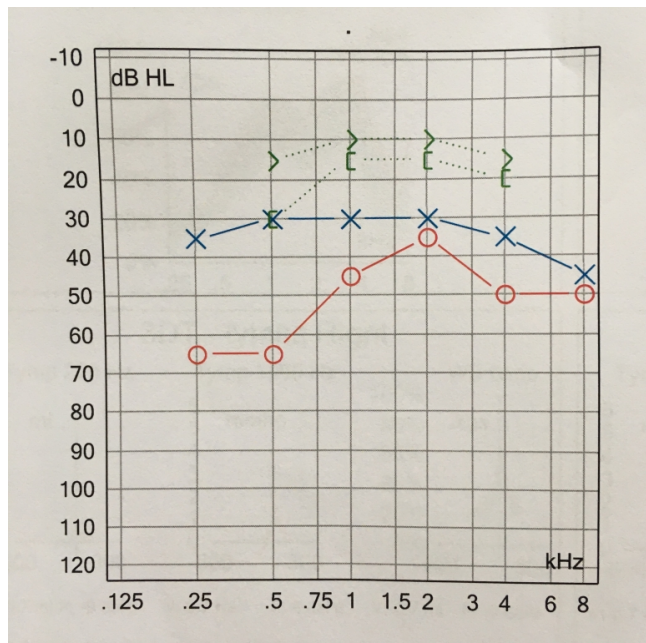


Figure 1

Patient's audiological test which on bilaterally conductive type hearing loss.

A temporal bone computer tomography (TBCT) was performed to enlighten the etiology and it showed the complete ossification of auricula and outer ear bilaterally. Auricular lobules, middle and inner ear canals were normal (Figure 2). The patient was diagnosed as a petrified auricle.

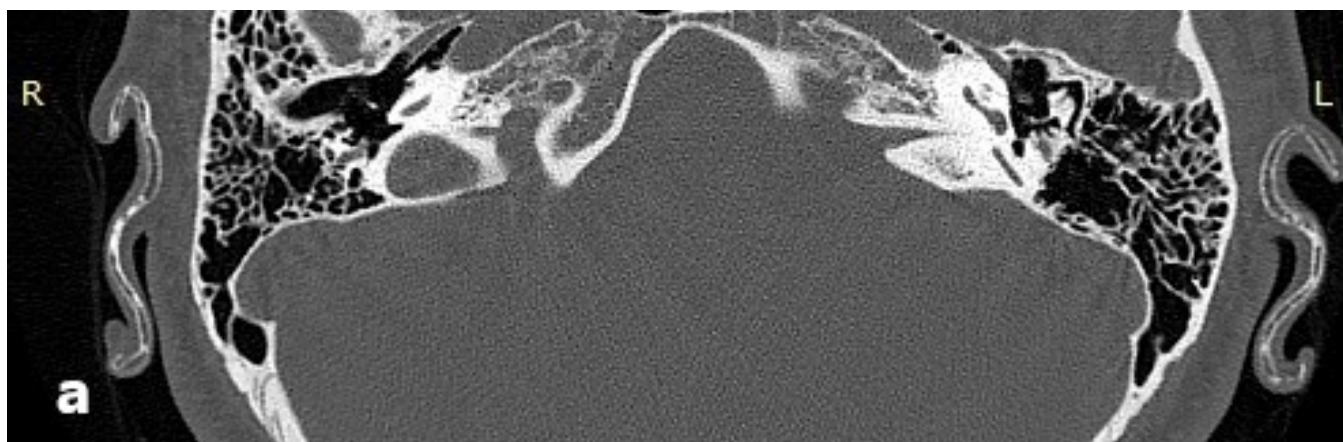


Figure 2A

Temporal bone computed tomography images of our patient (a) bilateral auricular ossifications which so-called petrified auricle on axial plane (b) ossifications of the bilateral external auditory canal in the cartilaginous parts on the coronal plane.

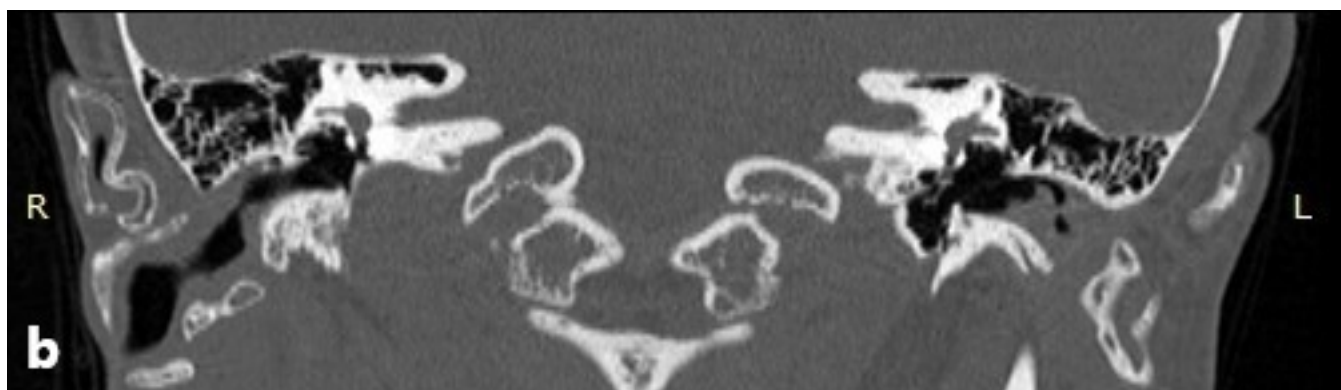

Figure 2B

Temporal bone computed tomography images of our patient (a) bilateral auricular ossifications which so-called petrified auricle on axial plane (b) ossifications of the bilateral external auditory canal in the cartilaginous parts on the coronal plane.

As this is no predisposing factor in history, various studies were performed to enlighten the etiology but the electrolytes, alkaline phosphatase, parathyroid hormone levels, thyroid function tests were all normal. The patient was suggested surgical treatment for the condition but was rejected.

Discussion

The frequency of petrified auricle was investigated by radiological and clinical studies. Aw J et al. evaluated TBCT of the patients who applied to their clinic and the reported prevalence of petrified auricle as 23.5%. [4] In the study of Gossner J on the prevalence of the petrified auricle, brain-computed tomography of 200 patients was evaluated and the ossification rate at any portion of the external ear was 19%, the auricle was involved in 6.5% and the complete ossification of the external ear was observed in only 0.5%. [5] On the other hand, Scherrer evaluated the ossification for the external ear via physical examination and found no palpable calcification/ossification. [6]

Partial or complete petrified auricle could be seen due to various reasons, mainly trauma. [2] Our patient was also questioned in terms of etiological factors but had no significant disease or predisposing factors in his medical history. The petrified auricle is usually asymptomatic because it could be localized in any region of the external ear and involvement of the external ear canal is rare. [7,8] Patients' complaints are usually severe pain with contact with the auriculae (such as contact with the pillow when lying down). Conduction-type hearing loss is caused by many reasons, but none of them are as rare as a petrified auricle. [4] Rarely, the external ear canal is also affected, as in our patient and the patient may apply with complaints of hearing loss. [6]

Calcification is defined as the accumulation of calcium salts in the tissue. Ossification occurs when calcium and phosphate precipitate as crystals of calcium hydroxyapatite in a protein matrix in the tissue. It is impossible to be understood by imaging methods that the petrified auricle is occurred by ossification or calcification in the external ear. The distinction between these two situations can be made by histopathologically. [9] However, histopathology is not necessary for diagnosis and petrified auricle can be diagnosed by demonstrating that the outer ear is ossified with TBCT. [4] We diagnosed a petrified auricle with TBCT that showing the ossification in the auricle and external auditory canal of our patient.

As petrified auricle is a rare disease there is no standardized treatment protocol and it is irreversible with the treatment of the underlying reason. Usually, no treatment is needed for asymptomatic patients, and surgical

interventions are possible for the symptoms.[10,11] Our patient was suggested surgical treatment and she rejected it.

This article presents a case of bilateral hearing loss due to petrified auricle and reviews the rare topic. It is thought that the paper is beneficial in terms of raising awareness. On the other hand, the petrified auricle is a rare diagnosis and more data is needed for the standardization of the management strategies. With the follow up of larger case series, an algorithm for both diagnosis and treatment could be created.

References

1. Bochdalek V. Verknocherung der Aurecula. Prag Vierteljahrschr. 1866;89:33-46.
2. Keane FM, Muller B, Murphy GM. Petrified ears. Clin Exp Dermatol 1997 Sep;22(5):242-3.
3. Laguna EV, Martinez AA, Burgos F. Petrified ear-a case of calcinosis cutis. Acta Derm Venerol 2009;89(5):527-8.
4. Aw J, Davies R, Cook JL. Stone deaf: the petrified ear-case report and review of the literature. Radiol Case Rep 2011Nov 6;6(2):430.
5. Gossner J. Prevalence of the petrified ear: a computed tomographic study. Eur Arch Otorhinolaryngol 2014 Jan;271(1):195-7.
6. Scherrer F. Calcification and ossification of the external ears. Ann Otol 1932;41:867-85.
7. Yeatman JM, Varigos GA. Auricular ossification. Australas J Dermatol 1998 Nov;39(4):268-70.
8. Lister GD. The petrified auricle: comments on ossification, calcification, and c.vostoses of the external ear. Laryngoscope 1985 May;95(5):566-76.
9. Sterneberg-Vos H, et al. Ossification of the auricle. Int J Dermatol 2007 Nov;46(3):42-4.
10. Lari AA, al-Rabah N, Dashti H. Acrobatic ears: a cause of petrified auricles. Br J Plast Surg 1989 Nov;42(6):719-21.
11. Alsey KJ, Freeman SR, Nigam A. Idiopathic bilateral auricular petrification. Ear Nose Throat J. 2012 Apr;91(4):1-2.