

IRREVERSIBLE SENSORINEURAL HEARING LOSS POST COVID 19

Otology

Submitted : 06.08.2021

Accepted : 29.03.2022

Published : 29.03.2022

Erkan Eşki¹¹ Başkent Üniversitesi, Zübeyde Hanım Uygulama ve Araştırma Merkezi**Özet****COVID 19 SONRASI GERİ DÖNÜŞÜ OLMAYAN SENSÖRİNÖRAL İŞİTME KAYBI**

Sensörinöral işitme kaybı kulak burun boğaz kliniklerinde sıklıkla görülmektedir. Patofizyolojisi hala bilinmemektedir. Ancak viral enfeksiyonlar sorumlu tutulmaktadır. 66 yaşında kadın hasta yoğun bakımdan çıktıktan sonra sol kulağında işitme kaybı şikayeti ile kliniğimize başvurdu. Hastanın herhangi bir vertigo, kulak ağrısı, baş dönmesi veya travma öyküsü yoktu. Covid 19 tanısıyla yoğun bakımda tedavi görmüştü. Başka bir hastalık veya ilaç kullanım öyküsü yoktu. Kulak burun boğaz muayenesi normaldi. Sağda Weber testi lateralize, solda rinne testi negatifti. Saf ses odyometrik muayenesinde sol kulakta 53 db SNHL saptandı. Biyokimyasal ve immünolojik parametreler normaldi. İç kulak manyetik rezonans görüntülemesi normaldi. İV 250 mg Prednizolon sonrası 1 mg/kg oral prednizolon ile tedavi edildi. Steroid tedavisine yanıt vermeyen hasta intratimpanik steroid önerisini kabul etmedi. Covid 19 sonrası işitme kaybı önemli bir morbidite nedeni olabilir ve kolaylıkla gözden kaçabilir. Covid 19 vakaları işitme kaybı açısından değerlendirilmelidir.

Anahtar kelimeler: sensörinöral işitme kaybı, Coronavirus, COVID-19

Abstract**IRREVERSIBLE SENSORINEURAL HEARING LOSS POST COVID 19**

Sensorineural hearing loss is frequently seen in ear, nose and throat clinics. Its pathophysiology is still unknown. However, viral infections are held responsible. A 66 year-old female patient was admitted to our clinic with hearing loss in her left ear after leaving intensive care. The patient did not have any background of vertigo, ear pain, dizziness or trauma. She was treated in the intensive care unit with the diagnosis of Covid 19. There was no history of any other disease or drug use. Otorhinolaryngologic examination was normal. Weber test was lateralized to the right and rinne test was negative on the left. In pure tone audiometric examination, 53 db SNHL was detected in the left ear. Biochemical and immunological parameters were normal. Inner ear magnetic resonance imaging was normal. After IV 250 mg Prednisolone, she was managed with 1 mg / kg oral prednisolone. The patient who did not respond to steroid treatment did not accept the intratympanic steroid recommendation. Hearing loss after Covid 19 can be an important cause of morbidity and can be easily overlooked. Cases with Covid 19 should be evaluated in terms of hearing loss.

Keywords: sensorineural hearing loss, Coronavirus, COVID-19

Introduction

The first case of Covid-19 was reported in China in December 2019. SARS-CoV-2 ,cause of Covid 19, is a virus that has the ability to be transmitted from person to person in direct contact or through droplets. The spread of the virus to the rest of China and the world was rapid. 2-14 days after the exposure to the virus, a variety of clinical features can be seen. The most common symptoms are muscle pain, fever, cough, shortness of breath, sore throat, headache, and taste and smell disorders. Age and immunocompromisation are important factors that increase susceptibility of severe infection, that might result in acute respiratory distress syndrome, organ failure, and death [1].

Sensorineural hearing loss(SNHL) is frequently seen in ear, nose and throat clinics.

Its pathophysiology is still unknown. However, viral infections are held responsible. SNHL is often attributed to different viral-related immune-mediated pathologies and can be a result of cellular stress response and vascular occlusion [2]. It has also been shown to cause intralabyrinth bleeding [3].

In two cross-sectional studies investigating the relationship between COVID-19 and SSNHL, first one found an increase in SSNHL cases during the pandemic period while a decrease was found in the second study [4,5]. The connection between COVID-19 and SNHL is not yet fully understood. In this article, the case of overlooked SNHL related with Covid 19 is presented.

Case Report

A 66 year-old female patient was admitted to our clinic with hearing loss in her left ear after leaving intensive care. The patient did not have any background of vertigo, ear pain, dizziness or trauma. She was treated in the intensive care unit with the diagnosis of Covid 19. There was no history of any other disease or drug use. Otorhinolaryngologic examination was normal. Weber test was lateralized to the right and rhinne test was negative on the left. In pure tone audiometric examination, 53 db SNHL was detected in the left ear.

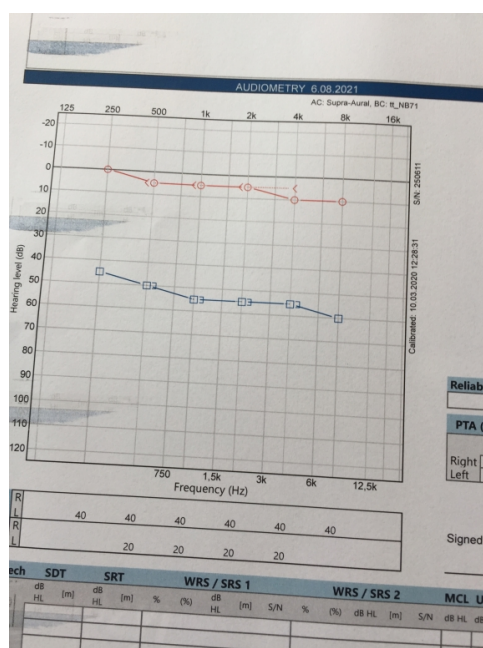


Figure 1
left sensorineural hearing loss

The tympanogram was normal.

Antineutrophil cytoplasmic antibody, anti-cardiolipin antibody, antinuclear antibody, and rheumatoid factor were negative. Immunoglobulin range, angiotensin converting enzyme count and complement C3 and C4 values were normal. Inner ear magnetic resonance imaging was normal. After IV 250 mg Prednisolone, she was managed with 1 mg / kg oral prednisolone. The patient who did not improve in his audiometric follow-up did not accept the intratympanic steroid recommendation. A clear etiology was not found for SNHL, but it has been suggested that may be related to covid 19. Informed consent was obtained.

Discussion

The first reported case of Covid 19-associated SNHL was in April 2020 by Sriwijitalai and Wiwanitkit in an elderly female from Thailand [6]. Later, Degen and colleagues detected total in right and severe in left ear SNHL during COVID-19 in a healthy 60-year-old male case. They applied cochlear implant to this case, which they stated that acute hearing loss occurred as a result of the spread of the meninges inflammation triggered by the virus to the cochlea [7]. On the other hand, severe sudden SNHL may develop during asymptomatic Covid 19 [8]. As can be seen in our case, the common feature for all of them is their moderate to severe sudden SNHL. Because of late detection, cases show a poor prognosis [6-8].

After case reports, studies were conducted to understand the relationship between COVID-19 and SNHL. Polymerase chain reaction applied by Kılıç et al. for Covid 19 to 5 cases who were admitted to their clinics with sudden SNHL. One of these cases was tested positive for SARS-CoV-2 and sudden SNHL was the only symptom the case had [9]. Cochlear involvement in asymptomatic COVID 19 cases was objectively demonstrated by otoacoustic emission measurements [10].

Investigation of hearing loss in patients with SARS-CoV-2 infection and more importantly, patients that are recovered from SARS-CoV-2 infection, is too important since the infection can lead to permanent hearing loss.

Conclusion

In conclusion, SNHL, a clinical symptom of SARS-CoV-2 infection, is emphasized with this case report. Permanent hearing loss decreases the patients' quality of life and as can be deduced from this report, early intervention in viral hearing loss can eliminate this possibility. Therefore, early detection is imperative.

References

1. Koumpa FS, Forde CT, Manjaly JG. Sudden irreversible hearing loss post COVID-19. *BMJ Case Rep*. 2020 Oct 13;13(11):e238419
2. Lang B, Hintze J, Conlon B. Coronavirus disease 2019 and sudden sensorineural hearing loss. *J Laryngol Otol*. 2020 Oct 1:1-3.
3. Chern A, Famuyide AO, Moonis G, Lalwani AK. Bilateral Sudden Sensorineural Hearing Loss and Intralabyrinthine Hemorrhage in a Patient With COVID-19. *Otol Neurotol*. 2021 Jan;42(1):e10-e14.
4. Fidan V, Akin O, Koyuncu H. Rised sudden sensorineural hearing loss during COVID-19 widespread. *Am J Otolaryngol*. 2021 Mar 31;42(5):102996.
5. Chari DA, Parikh A, Kozin ED, Reed M, Jung DH. Impact of COVID-19 on Presentation of Sudden Sensorineural Hearing Loss at a Single Institution. *Otolaryngol Head Neck Surg*. 2020 Nov 24:194599820974685. doi: 10.1177/0194599820974685. Online ahead of print.
6. Sriwijitalai W, Wiwanitkit V. Hearing loss and COVID-19: a note. *Am J Otolaryngol* 2020;41:102473.
7. Degen C, Lenarz T, Willenborg K. Acute profound sensorineural hearing loss after COVID-19 pneumonia. *Mayo Clin Proc* 2020;95:1801–3.
8. Rhman SA, Wahid AA. COVID-19 and sudden sensorineural hearing loss: a case report. *Otolaryngol Case Reports* 2020;16:100198.
9. Kilic O, Kalcioğlu MT, Cag Y, et al. Could sudden sensorineural hearing loss be the sole manifestation of COVID-19? An investigation into SARS-COV-2 in the etiology of sudden sensorineural hearing loss. *Int J Infect Dis* 2020;97:208–11.
10. Mustafa MWM. Audiological profile of asymptomatic Covid-19 PCR-positive cases. *Am J Otolaryngol* 2020;41:102483.

