

**MANAGEMENT OF A LARGE VALLECULAR CYST**

Head and Neck Surgery

Submitted : 03.06.2015

Accepted : 19.11.2015

Published : 19.11.2015

Sertaç Düzer<sup>1</sup>, Abdulvahap Akyiğit<sup>1</sup>, Öner Sakalhoğlu<sup>1</sup>, Cahit Polat<sup>1</sup><sup>1</sup> Elazığ Eğitim ve Araştırma Hastanesi**Özet****BÜYÜK VALLEKÜLER KİSTİN YÖNETİMİ**

Vallekuler kistler genellikle minör tükürük bezlerinin retansiyon kistidir. En sık meydana geldiği bölge epiglotun lingual yüzeyidir. Epiglottik mukus retansiyonları, aynı zamanda dil taban kistleri veya vallekuler kistler olarak bilinirler. Küçük vallekuler kistler asemptomatiktir. Bu vakalar çok farklı semptomlarla gelebilirler. Biz bu makalede büyük valleküler kistin neden olduğu disfaji ve dispne semptomuyla başvuran 60 yaşında erkek hastanın tanı ve tedavisini sunduk.

**Anahtar kelimeler:** Vallekula, büyük, Epiglot, Kist

**Abstract****MANAGEMENT OF A LARGE VALLECULAR CYST**

Vallecular cysts are usually retention cysts of the minor salivary glands. Common site of occurrence is lingual surface of epiglottis. Epiglottic mucous retentions, also known as vallecular cysts or base of tongue cysts. Small vallecular cysts are asymptomatic. These are may present different symptoms. In this latter, we describe the evaluation and treatment of a 60 year old man who presented with dysphagia and dispnea caused by large vallecular cysts.

**Keywords:** Vallecula, Large, Epiglottis, Cyst

**Introduction**

Laryngeal cysts constitute approximate %5 of benign laryngeal lesions [1]. The lingual surface of the epiglottis is the commonest site [2]. These cysts have been classified as ductal cysts, retention cysts and lymphoepithelial cysts. These are caused by inflammation, irritation, or trauma [3].

Laryngeal cysts are rare entities with sporadic occurrence and their prevalence and incidence are not precisely known. Epiglottic mucous retentions, also known as vallecular cysts or base of tongue cysts, are ductal cysts resulting from obstruction and retention of mucus in the collecting ducts of the submucosal glands located at the base of tongue [4].

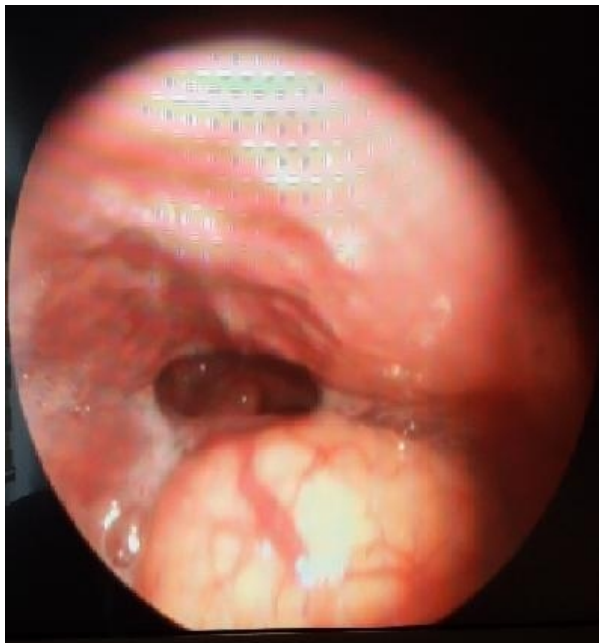Vallecular cysts are usually considered self-limiting lesions of the larynx, but in early infancy, this entity may be associated with severe airway obstruction and feeding difficulties [5-7]. In adults, vallecular cysts are most often asymptomatic and discovered on routine laryngoscopy or during induction of anesthesia. These cysts may present foreign body sensation in throat, dysphagia, dyspnea, voice change, and snoring [3].

We present a patient with large vallecular cyst who had complaints of foreign body sensation and pain in his throat during two years and applied many time to doctors due to his complaints.

**Case Report**

A 60 year old man who presented with change voice, dyspnea, dysphagia and a lump in his throat for two years. He have not any other systemic disease. He had previously been treated with an antiinflamatuar and antibiotics bias his

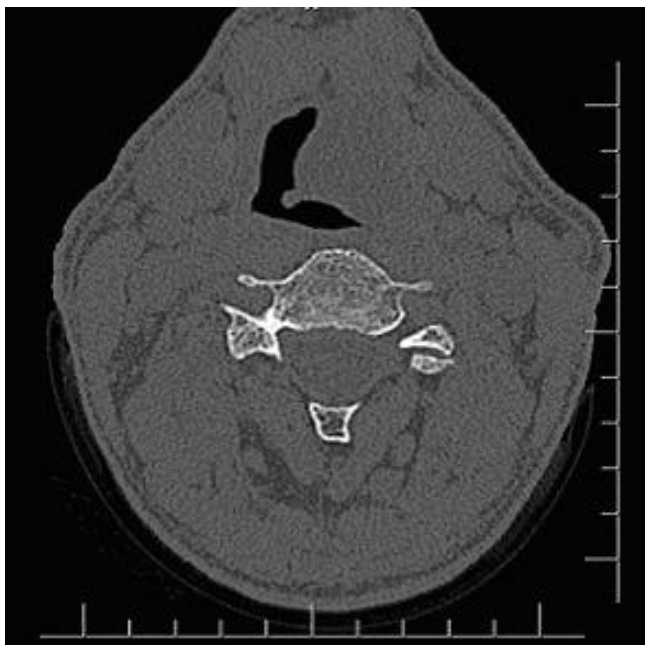
symptoms for upper airway infection. His otolaryngological examination was normal. But fibroscopic examination showed a large vallecular cyst (Figure 1).



**Figure 1**

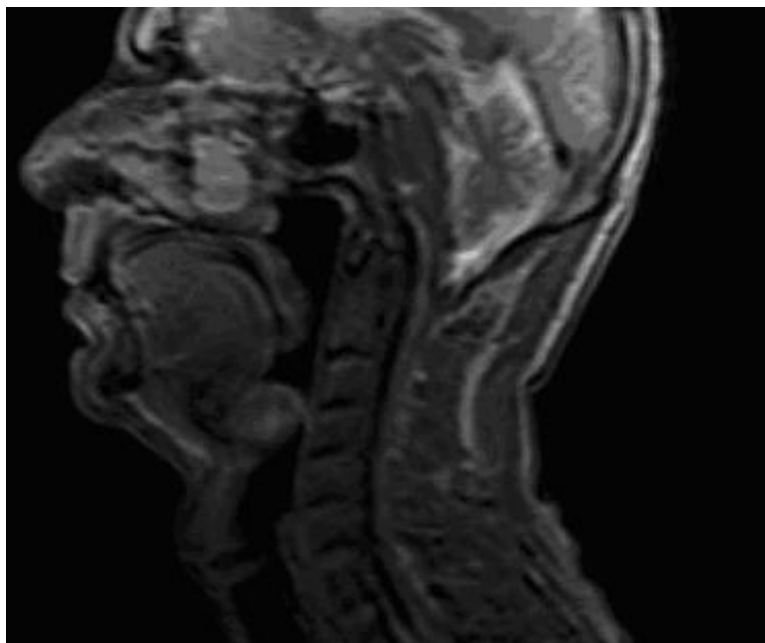
Preoperative endoscopic view of vallecular cyst

A computerized tomographic (CT) scan of the neck demonstrated a low density mass at epiglottis and vallecula (Figure 2). A magnetic resonance (MR) scan of the neck a large hyper-intensity cyst between base of tongue and epiglottis (Figure 3).



**Figure 2**

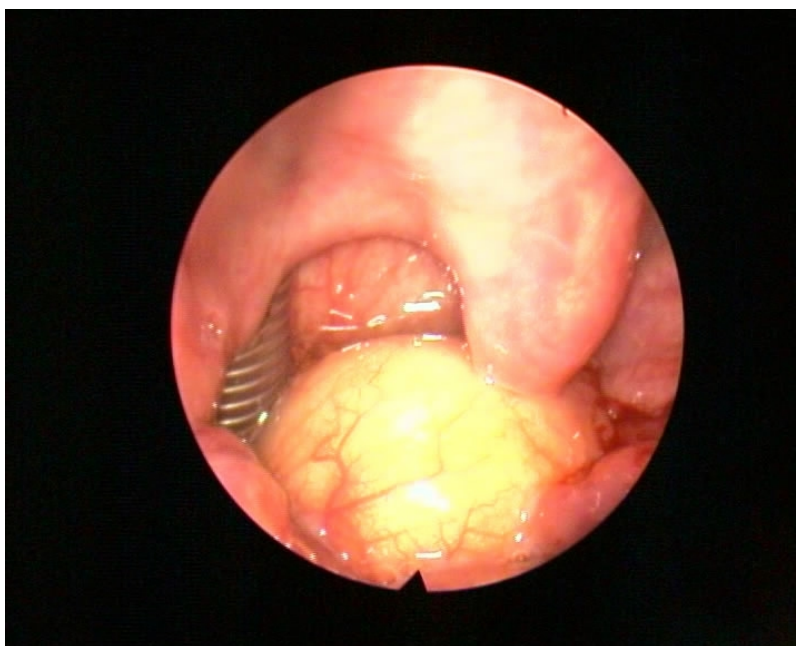
Axial CT image of neck



**Figure 3**

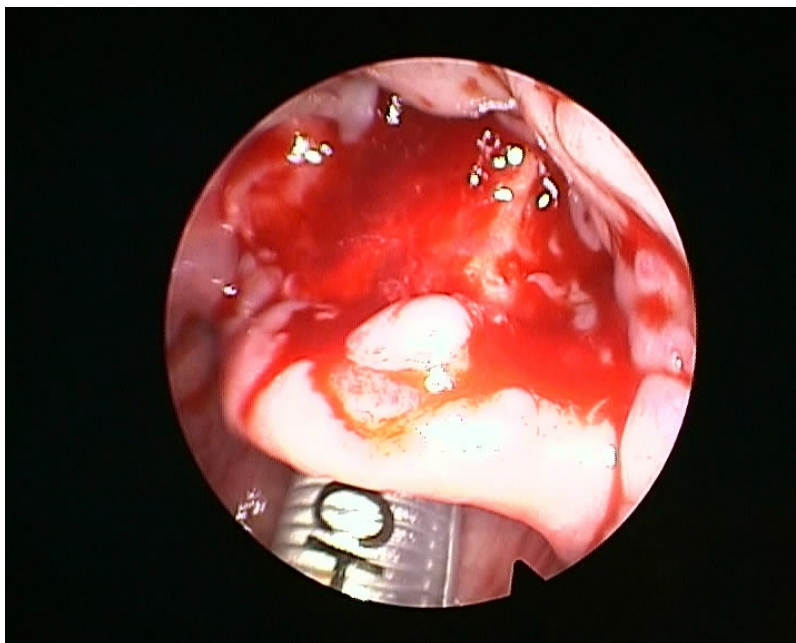
Sagittal MR image of neck

On the day of surgery, the patient was reassessed and particular attention was paid to his airway. The view of oropharyngeal structures was evaluated as Mallampati class 2. Based on the assessment and discussion with the anaesthetist. As patients with vallecular cyst have the potential for a difficult airway, in addition to tracheostomy and other difficult airway equipment, an otorhinolaryngology specialist was made available during anesthesia induction and tracheal intubation. Large-bore rigid suction catheters were also made immediately available in case of cyst rupture and bleeding. Under nasotracheal intubation with general anaesthesia (Figure 4), direct laryngoscopy and decompression of the cyst with a long laryngeal needle were performed. Then, the cyst edge visualized and cyst was marsupialized (Figure 5).



**Figure 4**

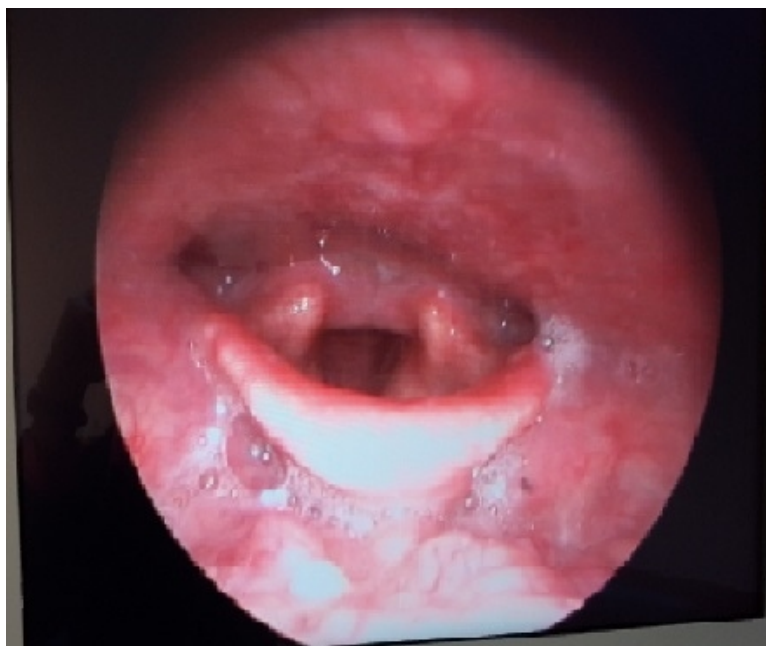Nasotracheal intubation of patient



**Figure 5**

Endoscopic view of vallecula after excision of cyst

Histopathological examination of the excised material confirmed a vallecular cyst. No problem arose during the course of anaesthesia, surgical intervention and the postoperative period, and the patient was discharged on the third postoperative day. Postoperative 10th day, the patient's examination was normal (Figure 6).



**Figure 6**

Postoperative 10th day. Endoscopic view of larynx

## Discussion

Laryngeal cysts are rare, the first reported case was published by Abercrombie J in 1881 [8]. Vallecular cysts are retention cysts of the minor salivary glands in the vallecula and base of tongue. Obstruction of the mucous glands leads to cyst formation and continued secretion leads to a corresponding increase in size of the cyst. Vallecular cysts accounts for 10,5% to 20,1% of all laryngeal cysts [9]. The most common location of epiglottic cyst is lingual

surface of the epiglottis. DeSanto et al. reviewed 238 cases of laryngeal cysts over a period of 10 years and found that 134(52%) were arising from the epiglottis [4]. The first classification was made by Myerson who divided of this cysts [10]. But the most popular one was postulated by DeSanto as ductal(75%) and saccular(25%) types [4]. Epiglottic cysts and vallecular cyst were attributed to the ductal type and are caused by obstruction of the submucous duct. Epiglottic cysts are specifically defined as cysts occurring at the lingual epiglottis. In adults, vallecular cyst are more common but less dangerous. Most adult epiglottic cysts are detected in the 6<sup>th</sup> decade of life, and the majority of cysts occur in men [3,6,11]. Presenting symptoms of epiglottic cysts vary with cyst size, age of the patient, as well as extension into the airway. Approximately two-thirds of vallecular cysts are asymptomatic and are diagnosed incidentally on routine laryngeal examination [3]. The incidence of vallecular cysts on laryngoscopy has been reported as 1 in 1250 to 1 in 4200, but their prevalence and incidence are not precisely known [12]. DeSanto et al. [4] stated that two separate clinical forms of vallecular cysts, with different pathogenesis and symptomatology. Majority of adult patients presenting with vallecular cysts may cause dysphagia and voice change. In infants and children it may also present with aero-digestive tract obstruction and stridor [6,13,14]. The differential diagnosis include internal thyroglossal duct cysts, dermoid cysts, lingual thyroid, teratomas, lymphangiomas and haemangiomas [15].

Bae et al. stated that a vallecular cyst in a patient with deep neck infection which cause difficult airway management [16]. Vallecular cysts can cause extreme problems in securing the airway. Meticulous airway assessment and contingency planning are mandatory, as with any difficult airway scenario. Close attention to logistics and the immediate availability of an otolaryngologist is vital [17].

Options for the treatment of vallecular cysts include wait and see, cyst aspiration, marsupialization, surgical debulking, microdebrider marsupialization, and laser excision [6,13,18-21]. In the case described here, the patient's large vallecular cysts which caused dysphagia, and hot potato voice. Vallecular cysts factor into the differential diagnosis of this symptoms. Managing vallecular cysts with direct laryngoscopy and excision may lead to resolution of symptoms.

## Conclusion

In adults, vallecular cysts are most often asymptomatic and discovered on routine laryngoscopy or during induction of anesthesia. However, vallecular cysts may lead to dysphagia, voice change, dyspnea and globus. In evaluating this symptoms, the presence of a vallecular cyst should be considered. The patients with the complaints of foreign body sensation, odynophagia and pain throat should be performed laryngeal endoscopic examination and laryngeal cysts should be considered in differential diagnosis. Nasotracheal intubation is useful in patients with vallecular cyst during the operation.

## References

1. Lam, H.C., V.J. Abdullah, and G. Soo, Epiglottic cyst. *Otolaryngol Head Neck Surg*, 2000. 122(2): p. 311.
2. Walshe, C.M., N. Jonas, and D. Rohan, Vallecular cyst causing a difficult intubation. *Br J Anaesth*, 2009. 102(4): p. 565.
3. Arens, C., H. Glanz, and O. Kleinsasser, Clinical and morphological aspects of laryngeal cysts. *Eur Arch Otorhinolaryngol*, 1997. 254(9-10): p. 430-6.
4. DeSanto, L.W., K.D. Devine, and L.H. Weiland, Cysts of the larynx--classification. *Laryngoscope*, 1970. 80(1): p. 145-76.
5. Mitchell, D.B., et al., Cysts of the infant larynx. *J Laryngol Otol*, 1987. 101(8): p. 833-7.
6. Gutierrez, J.P., R.G. Berkowitz, and C.F. Robertson, Vallecular cysts in newborns and young infants. *Pediatr Pulmonol*, 1999. 27(4): p. 282-5.
7. Hsieh, W.S., et al., Vallecular cyst: an uncommon cause of stridor in newborn infants. *Eur J Pediatr*, 2000.



- 159(1-2): p. 79-81.
8. Abercrombie, J., Congenital cyst in larynx. Transaction of the Pathological Society in London 1881; 32: 33-34.
  9. Romak, J.J., et al., Bilateral vallecular cysts as a cause of Dysphagia: case report and literature review. Int J Otolaryngol. 2010; p. 697583.
  10. Myerson, M.C., Cysts of the Larynx , Arch. Otolaryng. 1933; 18:281-290.
  11. Reichard, K.G. and J. Weingarten-Arams, Radiological case of the month. Epiglottic cyst. Arch Pediatr Adolesc Med, 1998. 152(12): p. 1237-8.
  12. Mason, D.G. and K.J. Wark, Unexpected difficult intubation. Asymptomatic epiglottic cysts as a cause of upper airway obstruction during anaesthesia. Anaesthesia, 1987. 42(4): p. 407-10.
  13. KU, A., Vallecular cyst: report of four cases--one with co-existing laryngomalacia. J Laryngol Otol. 2000 Mar;114(3):224-226.
  14. Tuncer, U., L.B. Aydogan, and L. Soylu, Vallecular cyst: a cause of failure to thrive in an infant. Int J Pediatr Otorhinolaryngol, 2002. 65(2): p. 133-5.
  15. Bnahdary, S., Innovative Surgical Technique in the Management of Vallecular Cyst. Online J Helath Allied S cs. 2003:3:2.
  16. Bae, H.M., et al., A vallecular cyst in a patient with deep neck infection causing difficult airway management. Korean J Anesthesiol. 2014. 67(Suppl): p. S21-2.
  17. Kothandan, H., et al., Difficult intubation in a patient with vallecular cyst. Singapore Med J. 2013.54(3): p. e62-5.
  18. Leibowitz, J.M., et al., Diagnosis and treatment of pediatric vallecular cysts and pseudocysts. Int J Pediatr Otorhinolaryngol. 2011. 75(7): p. 899-904.
  19. Chen, E.Y., et al., Transoral approach for direct and complete excision of vallecular cysts in children. Int J Pediatr Otorhinolaryngol. 2011. 75(9): p. 1147-51.
  20. Pagella, F., et al., Transoral power-assisted marsupialization of vallecular cysts under local anesthesia. Laryngoscope. 2013. 123(3): p. 699-701.
  21. Liu, X., et al., [Application of electric coagulation treatment via bronchoscopy in the management of congenital vallecular cyst in children]. Zhonghua Er Ke Za Zhi. 2013. 51(11): p. 846-8.