

LIFE-THREATENING CERVICAL NECROTIZING FASCIITIS CAUSED BY KLEBSIELLA PNEUMONIAE : A RARE CASE

Head and Neck Surgery

Submitted : 07.11.2022

Accepted : 08.06.2023

Published : 08.06.2023

Mustafa Dalgıç¹, Deniz Baklacı¹, Ergin Bilgin¹

¹ Bülent Ecevit Üniversitesi Tıp Fakültesi

Özet

KLEBSIELLA PNEUMONIA ETKENİNE BAĞLI OLUŞAN, HAYATI TEHDİT EDEN NADİR BİR BOYUNDA NEKROTİZAN FASİİT OLGUSU

Nekrotizan fasiit nadir görülen, progresif ve hayati tehdit eden bakteriyel bir enfeksiyondur. Hızlı bir şekilde fasya planlarına ve subkutanöz dokulara yayılarak doku nekrozuna ve sıklıkla ölüme neden olmaktadır. Hızlı bir şekilde yayılan nekroza bağlı olarak sistemik sepsis, toksik şok sendromu ve çoklu organ yetmezliği görülebilmektedir. Genellikle odontojenik veya faringeal odaklardan mix flora mikroorganizma etkinliği ile görülmektedir. Boyundan aşağı bölgelere yayılması ve mediastinal tutulum ana komplikasyonları oluşturmaktadır. Tedavi başarısında erken tanı, uygun antibiyotik kullanımı ve cerrahi debritleme önemlidir. Bu olgu sunumunda, diş enfeksiyonuna bağlı boyunda nekrotizan fasiit gelişen diyabetik bir hasta literatür eşliğinde tartışıldı

Anahtar kelimeler: nekrotizan fasiit, klebsiella pneumonia, apse

Abstract

LIFE-THREATENING CERVICAL NECROTIZING FASCIITIS CAUSED BY KLEBSIELLA PNEUMONIAE : A RARE CASE

Necrotizing fasciitis is a rare, progressive and life-threatening bacterial infection which spreads with frightening speed along the fascial planes and subcutaneous tissue resulting in extensive tissue necrosis and often death. Rapidly spreading necrosis often causes systemic sepsis, toxic shock syndrome and multiple organ failure. The origin is generally odontogenic or pharyngeal, involving a mixed flora of microorganisms. Descending infection and mediastinal involvement are usually associated and are the main complications. Factors affecting the success of the treatment of necrotizing fasciitis are early diagnosis, appropriate antibiotics and surgical debridement. This article is presented in a diabetic patient with necrotizing fasciitis of the neck originated from odontogenic infection. Clinical features, pathogenesis and treatment of the case are discussed with the literature

Keywords: necrotising fasciitis, klebsiella pneumonia, abscess

Introduction

Necrotising fasciitis (NF) is a rare and life-threatening infection which spreads along the fascial planes and subsequently causes necrosis of subcutaneous fat, skin and sometimes muscle. Infection primarily involves the superficial fascia and progresses into surrounding tissues; progress is often fulminant and may involve all soft-tissues components [1]. Necrotising fasciitis occurs more commonly in patients with compromised immune systems, and more frequently in the abdominal wall, perineum, and extremities [2]. NF rarely involves the head and neck region; and if it occurs, it is usually due to the spread of infection from the teeth or pharynx [3]. Cultures from cervical necrotising fasciitis with a dental source are more likely to include anaerobes, whereas cases associated with pharyngeal mucosa or skin trauma more likely include Staphylococcus and Streptococcus species [4,5]. Cervical necrotizing fasciitis caused by Klebsiella pneumoniae, however, is a rare entity. Necrotizing fasciitis of the head and neck has a particularly high mortality rate due to the proximity of many vital anatomical structures.

Corresponding Author: Mustafa Dalgıç, Bülent Ecevit Üniversitesi Tıp Fakültesi İbni Sina Kampüsü, Esenköy, Kozlu, Zonguldak dalgic_816@hotmail.com

Dalgıç M, Baklacı D, Bilgin E. Klebsiella pneumonia etkenine bağlı oluşan, hayati tehdit eden nadir bir boyunda nekrotizan fasiit olgusu. ENTcase. 2023;9(2):79-85

Known complications of cervical necrotizing fasciitis include airway compromise, arterial and venous occlusion and the extension of infection into the mediastinal and pleural spaces [6]. Treatment of the disease is early diagnosis, a careful aggressive debridement, parenteral antibiotic treatment, and supporting treatment controlling an underlying preparative, and aggravating factors.

Case Report

A 75 year old male with known history of diabetes mellitus presented to Bulent Ecevit University, Otorhinolaryngology – Head and Neck Surgery Department with a history of progressive neck swelling and dysphagia for one week. On examination, he was drowsy and dehydrated with poor oral hygiene and no evidence of respiratory compromise. He demonstrated swelling and tenderness over the right neck extending sternal notch (Figure1). Palpation revealed crepitation on right side of the neck region. On physical examination right lower molar teeth decay was noticed. Indirect laryngoscopy was performed to evaluate the airway status. On indirect laryngoscopy, laryngeal examination was normal and the airway was patent. Other otolaryngologic examinations were normal. Laboratory work was remarkable, with a white blood cell count of $16.6 \times 10^9/L$, C-reactive protein (CRP) level of 143 mg/L, and glucose level of 216 mg/dL. Empirical broad spectrum antibiotics (ceftriaxone and metronidazole) were started.

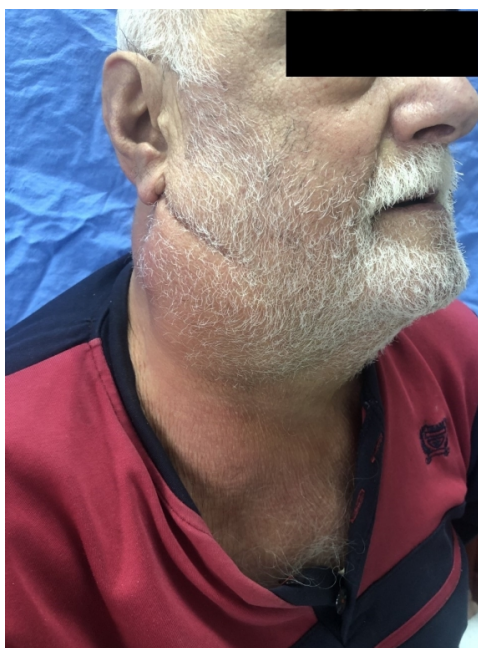

Figure 1

The patient demonstrated swelling and tenderness over the right neck extending sternal notch.

Computerised tomography(CT) scan showed an extensive hypodense collection with air pockets in the right servical region. It was also noted that the extensive collection involves internal jugular vein (Figure 2).

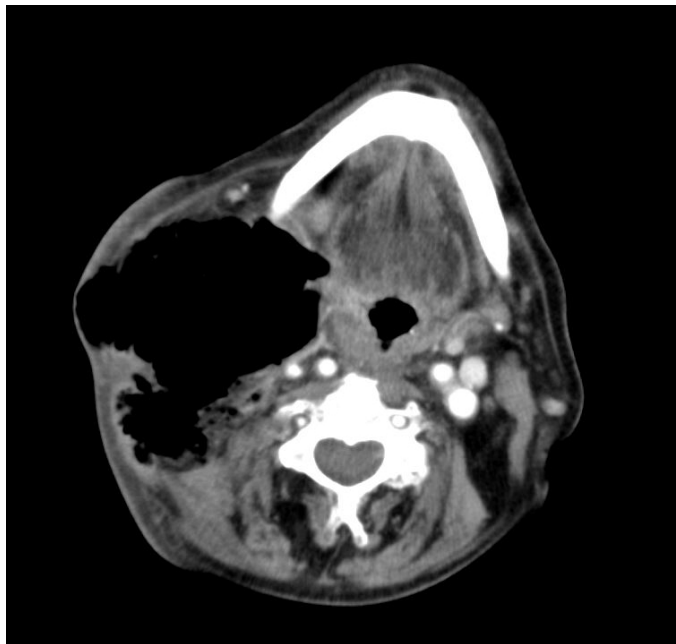


Figure 2

CT scan showed an extensive hypodense collection with air pockets in the right cervical region.

After first evaluation of the patient, the clinical examination and neck ct scan signs were suggested that the diagnosis was necrotising fasciitis on neck. The patient was admitted. Immediate neck exploration and debridement under general anesthesia was planned. Informed consent was obtained from the patient for treatment and surgery. Under general anesthesia, an extensive debridement was done where all the deep fascial planes of the right side of the neck and part of the anterior chest wall was debrided until there was evidence of fresh bleeding from the skin edges. The right internal jugular vein was found exposed. Necrotic tissues and purulent materials were debrided, and the wound was left open (Figure 3). Histologic findings showed gas inclusions between the muscle fibres and subfascial planes (Figure 4). *Klebsiella* species was isolated from the wound. Antibiotic sensitivity test showed that isolated *Klebsiella* species was sensitive to ceftriaxone, gentamicin, ciprofloxacin and trimethoprim/sulfamethoxazole.

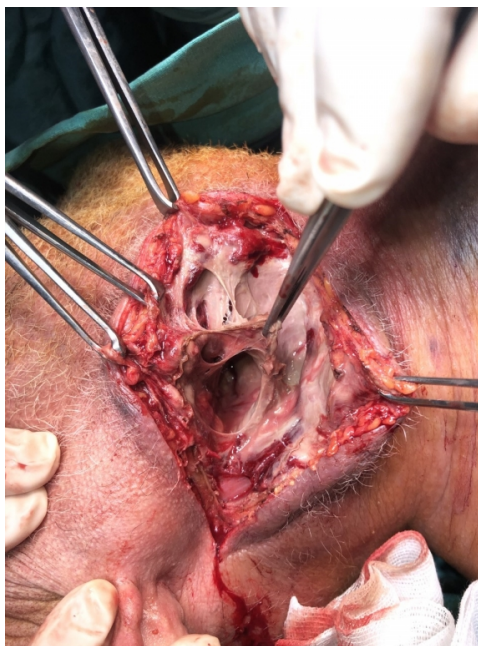

Figure 3

Neck exploration was performed. Necrotic tissues and purulent materials were debride, and the wound was left open.

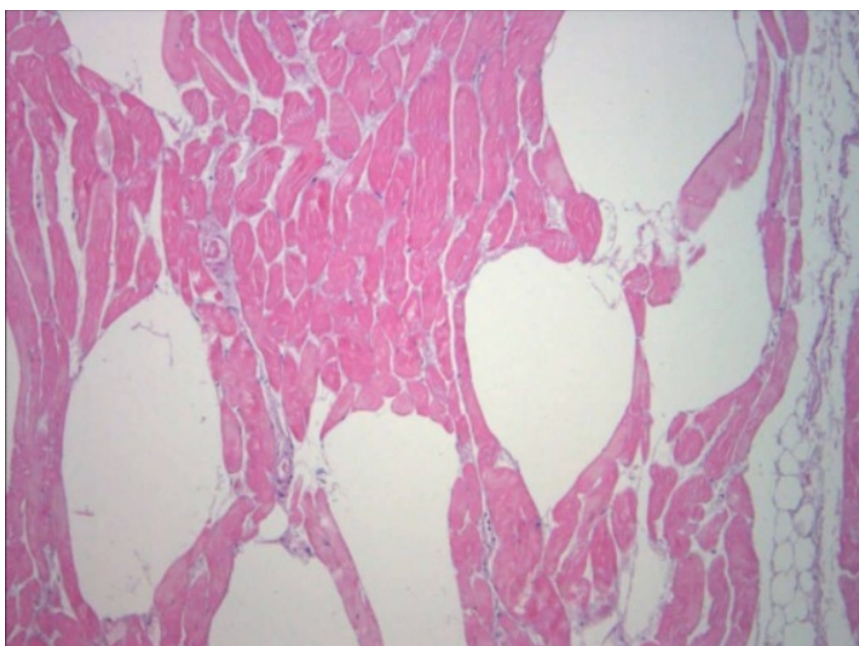


Figure 4

An example of the pathologic findings of the muscle tissue obtained during surgical removal. Infected tissue with gas inclusion between the muscle fibres can be seen.

The wound was dressed and debrided daily, and closed with antibiotic gas. The CT scan of the neck showed significant improvement of the infection (Figure 4). The wound granulated well after two weeks and was closed in the event that the wound area epithelised (Figure 5). The patient being discharged on hospital day 14 on oral ciprofloxacin. On the first month after the surgery, the wound was totally healed.

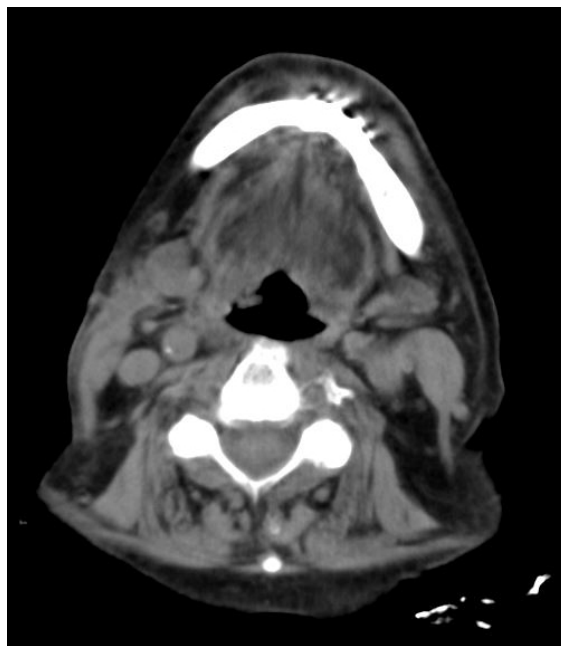


Figure 4

The post-treatment CT scan of the neck showed significant improvement of the infection.

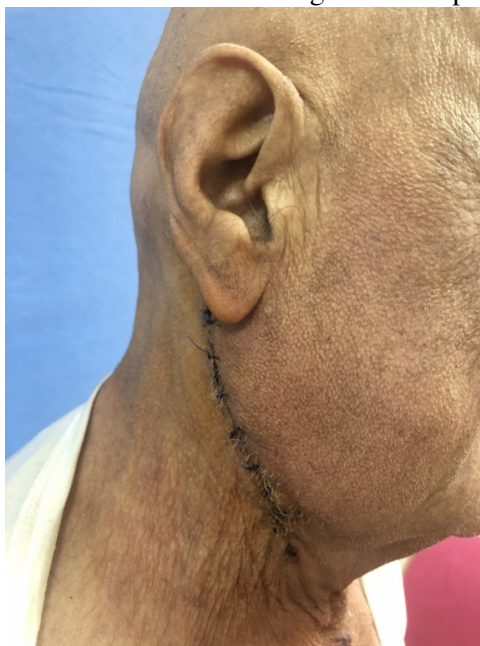

Figure 5

The wound granulated well after two weeks and was closed in the event that the wound area epithelised

Discussion

Necrotising fasciitis is a severe and potentially fatal infection of the dermal, fascial and subcutaneous layers of the skin. The causative organisms are commonly Group A Beta Haemolytic Streptococci or Staphylococcus Aureus as single agent or may be a polymicrobial infections. Polymicrobial infections are caused by mixed aerobic and anaerobic pathogens. Streptococcus pyogenes (group A Streptococcus) is the most classic pathogen [7]. Monomicrobial Klebsiella Pneumonia necrotising fasciitis accounted for 11% of all NF cases [8]. Necrotizing fasciitis of the head and neck region is uncommon [9]. In a large series of 128 cases of necrotizing fasciitis, only five of them involved the head and neck region [10]. The commonest cause of cervical necrotising fasciitis is

dental infections. Dental infection of the second or third molar teeth may cause cervicofacial infection. This is because the roots of these molars extend below the insertion of the mylohyoid muscle, which is connected to the submandibular space [11]. Immunocompromised patients and patients with systemic disease such as diabetes mellitus are at an increased risk of developing this infection. Descending infection and mediastinal involvement are usually associated and are the main complications [12].

Hsiao et al. reported that the most common symptoms were swelling and pain, which occurred in 71.1% and 54.7% of cases, respectively [10]. Dysphagia and odynophagia are also common symptoms [13]. Our patient was diabetic and had swelling and tenderness over the right neck extending sternal notch.

CT imaging is useful in the diagnosis of the necrotising fasciitis. CT characteristics correlate with pathologic findings of soft-tissue inflammation or liquefactive necrosis and thus may feature dermal thickening, increased soft-tissue attenuation, inflammatory fat stranding, and possible superficial or deep crescentic fluid or air in the subfascial planes [14,15]. In our patient, CT scan showed an extensive hypodense collection with air pockets in the right servical region. It was also noted that the extensive collection involves internal jugular vein. MRI is the modality of choice for detailed evaluation of soft-tissue infection but is often not performed for necrotizing fasciitis evaluation because its acquisition is time consuming and will delay treatment [16,17].

The first step of treatment is securing the airway. If the airway is compromised, early intubation or tracheostomy should be considered. Early aggressive surgical intervention with eradication of the source of infection is important. Besides surgical treatment, broad spectrum empiric antibiotics should be initiated. Initial treatment should cover the most commonly involved microorganisms, such as group A Streptococcus and anaerobes, and nowadays is extended to gram-negatives such as Klebsiella Pneumonia and Staphylococcus. However, prior studies of Klebsiella Pneumoniae infection have found no significant association between appropriate empiric antibiotic treatment and outcomes [18,19]. In addition, regular and frequent debridement with appropriate wound dressing is helpful for better outcomes. In this case, after first evaluation of the patient, immediate neck exploration and debridement under general anesthesia was performed. Empirical broad spectrum antibiotics (ceftriaxone and metronidazole) were immediately started. The wound left open and was dressed and debrided daily, and closed with antibiotic gas. After two weeks, the wound healed and the patient was discharged.

Informed Consent: Hastadan

References

1. Wong, Chin-Ho et al. "Necrotizing fasciitis: clinical presentation, microbiology, and determinants of mortality." *The Journal of bone and joint surgery. American volume* vol. 85,8 (2003): 1454-60.
2. Brunworth J, Shibuya TY. Craniocervical necrotizing fasciitis resulting from dentoalveolar infection. *Oral Maxillofac Surg Clin N Am* 2011;23:425e32.
3. Shindo ML, Nalbone VP, Dougherty WR. Necrotizing fasciitis of the face. *Laryngoscope*. 1997;107:1071-1079
4. Mao JC, Carron MA, Fountain KR, et al. Craniocervical necrotizing fasciitis with and without thoracic extension: management strategies and outcome. *Am J Otolaryngol* 2009;30:17-23.
5. Fihman, V et al. "Cervical necrotizing fasciitis: 8-years' experience of microbiology." *European journal of clinical microbiology & infectious diseases* : official publication of the European Society of Clinical Microbiology vol. 27,8 (2008): 691-5.
6. Banerjee AR, Murty GE, Moir AA. Cervical necrotizing fasciitis: a distinct clinicopathological entity? *J Laryngol Otol*. 1996;110:81-86.
7. McHenry, C R et al. "Determinants of mortality for necrotizing soft-tissue infections." *Annals of surgery* vol. 221,5 (1995): 558-63; discussion 563-5.

8. Cheng, Nai-Chen et al. "Recent trend of necrotizing fasciitis in Taiwan: focus on monomicrobial *Klebsiella pneumoniae* necrotizing fasciitis." *Clinical infectious diseases : an official publication of the Infectious Diseases Society of America* vol. 55,7 (2012): 930-9.
9. Bono, Giovanna et al. "Cervical necrotizing fasciitis and descending necrotizing mediastinitis in a patient affected by neglected peritonsillar abscess: a case of medical negligence." *Journal of forensic and legal medicine* vol. 15,6 (2008): 391-4.
10. Hsiao, Cheng-Ting et al. "Predictors of mortality in patients with necrotizing fasciitis." *The American journal of emergency medicine* vol. 26,2 (2008): 170-5.
11. De Backer T, Bossuyt M, Schoenaers J. Management of necrotizing fasciitis in the neck. *J Craniomaxillofac Surg.* 1996;24:366–371.
12. Karkas, A et al. "Optimal treatment of cervical necrotizing fasciitis associated with descending necrotizing mediastinitis." *The British journal of surgery* vol. 97,4 (2010): 609-15.
13. Lin, C et al. "Necrotizing fasciitis of the head and neck: an analysis of 47 cases." *Plastic and reconstructive surgery* vol. 107,7 (2001): 1684-93.
14. Struk, D W et al. "Imaging of soft tissue infections." *Radiologic clinics of North America* vol. 39,2 (2001): 277-303.
15. Becker, M et al. "Necrotizing fasciitis of the head and neck: role of CT in diagnosis and management." *Radiology* vol. 202,2 (1997): 471-6.
16. Eke N. Fournier's gangrene: a review of 1726 cases. *Br J Surg* 2000; 87:718–728
17. Turecki, Marcin B et al. "Imaging of musculoskeletal soft tissue infections." *Skeletal radiology* vol. 39,10 (2010): 957-71.
18. Thom, Kerri A et al. "Impact of empiric antimicrobial therapy on outcomes in patients with *Escherichia coli* and *Klebsiella pneumoniae* bacteremia: a cohort study." *BMC infectious diseases* vol. 8 116. 15 Sep. 2008.
19. Chuang, T-Y et al. "Positive culture for *Klebsiella pneumoniae* in relevant sputum samples as a predictor of rapidly fatal outcome in septic patients at medical intensive care units." *European journal of clinical microbiology & infectious diseases : official publication of the European Society of Clinical Microbiology* vol. 29,8 (2010): 969-75.