

RHINOLITHIASIS: REVIEW OF THE LITERATURE WITH CASE REPORTS

RİNOLİTİAZİS: OLGU SUNUMLARI VE KISA LİTERATÜR
DERLEMESİ
Rinoloji

Başvuru: 24.10.2015
Kabul: 18.11.2015
Yayın: 18.11.2015

Erdem Atalay Çetinkaya¹, Murat Gümüüşsoy²

¹ Sağlık Bilimleri Üniversitesi, Antalya SUAM
² Tepecik Eğitim ve Araştırma Hastanesi

Özet

Rhinolithiasis, endojen veya eksojen burun yabancı cisim etrafında organik ve inorganik bileşikler birikimi sonucu oluşan kalsifiye kitlelerdir. Genellikle tek vaka çalışmaları literatürde bildirilmiştir. Bu çalışma bir dizi rhinolithiasis olgusunun klinik bulguları, tanı, tedavi ve mineralojik bileşim analizleri literatür gözden geçirilerek sunulmuştur. Klinik bulgular ; tekrarlayan pürülan burun akıntısı, ağız kokusu ve rinolit tarafından uyarılan yüz ağrısı olarak kaydedildi. Rhinolitler endoskopik olarak çıkarıldı. Rinolit mineralojik analizi, kalsiyum fosfat ve kalsiyum hidroksit karışımı olarak değerlendirildi. Gençler ve yetişkinler nadir olmakla birlikte, rinolit her zaman, özellikle tek taraflı kötü kokulu burun akıntısı ve ağız kokusu ile başvuran bir hastada bir ayırıcı tanısında düşünülmelidir.

Anahtar kelimeler: Rinolit, Rinolithiazis Halitozis

Abstract

Rhinolithiasis is calcified masses that result from the organic and inorganic compounds deposition around an endogenous or exogenous intranasal foreign body. It is generally reported in the literature in single case studies. This study presents 3 cases of rhinolithiasis with a series of clinical findings, diagnosis, treatment , analyses of the removed rhinoliths mineralogical composition and to review the literature. The common symptoms were noted as recurrent purulent rhinorrhea , halitosis and facial pain induced by rhinolith. Rhinoliths were excised by endoscopically. Mineralogical analysis of the extracted rhinolith was evaluated as calcium phosphate and calcium hydroxide mixture. Although relatively rare in teenagers and adults, rhinoliths should always be considered of a differential diagnosis in a patient presenting with especially unilateral foul-smelling nasal discharge and oral malodor.

Keywords: Rhinolith, Rhinolithiasis Halitosis

Introduction

Rhinoliths are rare, calcareous concretions that are formed by the deposition of organic and inorganic compounds on an intranasal foreign body. The foreign body, which acts as the nucleus for encrustation, can be either endogenous or exogenous. Although the pathogenesis remains unclear, a number of factors are thought to be involved in the formation of rhinoliths development and progression are believed to take a number of years [1]. As the rhinolith increases in size, the symptoms may range from unilateral nasal discharge to septal perforation [2]. The diagnosis is based on the medical history and endoscopic findings. An imaging modality may provide additional information . The treatment of choice is surgical removal under local or general anaesthesia [3]. Aim of the present report is to describe three cases of rhinolithiasis and to review the literature.

Case Report

Case 1

Sorumlu Yazar: Erdem Atalay Çetinkaya, Sağlık Bilimleri Üniversitesi, Antalya SUAM
Sağlık Bilimleri Üniversitesi , Antalya SUAM, KBB Kliniği
drerdemcetinkaya@gmail.com

A 21-year-old female was referred to our clinic for by snatches nasal discharge, halitosis and facial pain. Rhinoscopy showed presence of brief purulent secretion and irregular surface calcified mass, which was dark green and recovered by granulation tissue, stone-hard upon touch with suction. It was immovable, obstructing the left nasal septum and inferior conchae, with nasal septum deviation to the right. However, there was no history of nasal block, epistaxis or foreign body in the nose. The rhinolith was completely removed by application of local anaesthesia as outpatient .On crushing the rhinolith, the bead was identified (Figure 1).



Figure 1

The rhinolith, the bead seen inside (under 3D microscope)

Case 2

A 6-year-old boy presented to our clinic complaining of unilateral purulent rhinorrhea , halitosis. Extranasal examination revealed purulent nasal discharge in the right nasal aperture. There was no history of foreign body insertion but his mother said that he suffered from nasal congestion. After suction, rhinoscopy showed a heterogeneous, diffuse calcified grey mass in the right nasal cavity. The mass was removed under general anesthesia in the operating room and crushing the rhinolith, the sponge was identified (Figure 2).




Figure 2

The rhinolith, the sponge seen inside (under 3D microscope)

Case 3

A 14 -year-old female reported nasal obstruction, only on the left nasal fossa, intermittent, that progressed to continuous obstruction, with anterior and posterior purulent discharge and halitosis. She said that at the age of 5 years she introduced a nut into the left nostril, which was removed and she had remained without complaints up to the current presentation.. An intranasal examination using a speculum and Rigid nasal endoscope revealed a grayish-white irregular stone-hard mass along the floor of the left nasal cavity just below the inferior turbinate. The rhinolith was completely removed by application of local anaesthesia as outpatient .On crushing the rhinolith, the nut fragment was identified (Figure 3).

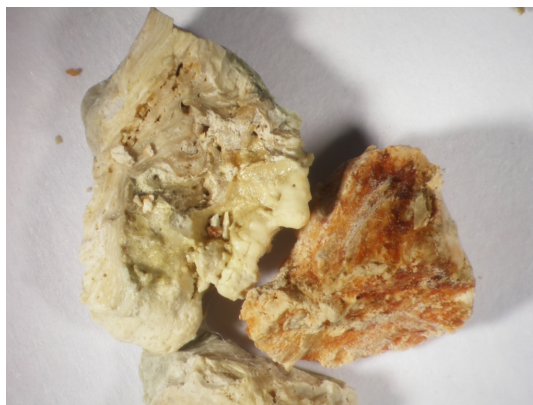

Figure 3

The rhinolith, the nut fragment seen inside (under 3D microscope)

Mineralogical analysis of the three extracted rhinolith was evaluated as calcium phosphate and calcium hydroxide mixture.

Discussion

The first documented case of rhinolith was reported by Bartholin in 1654; the first chemical analysis was conducted by Axmann in 1829; and the first radiographic description of a rhinolith was published by MacIntyre in 1900. However, case reports of rhinolith still remain relatively rare in the literature. Rhinoliths result from neglected nasal foreign bodies that gradually increase in size. Factors that contribute to the calcification process are physical such as stasis of nasal secretions, changes in airflow and chemical such as pH changes, hypersaturation of secretions, infection, acute or chronic inflammation, the enzymatic activities of bacterial pathogens [4]. Rhinoliths are believed to be formed by the deposition of magnesium, iron, calcium, phosphorus around a core, in addition to organic substances such as glutamic acid and glycine, leading to slow and progressive increase in size. The central core can be intranasal endogenous or exogenous foreign material. The endogenous central core could be due to desiccated blood clots, sequestra, ectopic teeth and bone fragments following trauma. The exogenous central cores, which include foreign bodies placed in the nose usually during childhood, are the most common origin. These foreign bodies usually include beads, buttons, plant material, seeds of fruits, cotton, foam fragment, fragments of wood, pieces of paper, pieces of plastic, retained nasal and dental impression material.

Rhinoliths usually present in the second and third decade of life and rarely occur in children; females are more commonly affected than males [3]. In our review, 2 female and 1 male patients; ranged from 6 to 21 years of age were observed. All of them had exogenous central cores, which include foreign bodies.

They are usually found in floor of the nose, about halfway between the anterior and posterior portion of the nares [5]. Symptoms are normally progressive unilateral nasal obstruction, rhinorrhea. Small sized rhinoliths are usually asymptomatic. Larger ones may cause unilateral nasal discharge, facial pain, nasal obstruction, foul smelling breath, halitosis, epistaxis, headache, nasal or facial swelling, sinusitis and anosmia or remain asymptomatic. Erosions of the septum, maxillary sinus, and perforations have also been cited in literature. Our patients presented with foul-smelling nasal discharge and breath, halitosis, nasal congestion and facial pain. It can perhaps be suggested that rhinolith can cause facial pain by direct stimulation, referred pain or by causing mucosal contacts. As in our cases, rhinoliths are generally unilateral. Rarely, bilateral rhinoliths may be observed [4-9]. In literature, there are unusual presentations of rhinolithiasis with squamous cell carcinoma and polyp in the nasal cavity [10,11].

Diagnosis is normally based on symptomatology, history of foreign body introduction into the nose, physical examination and complementary tests. A Computed tomography (CT) or cone beam CT scan is recommended due to its sensitivity in recognizing even small amounts of calcification and it also provides information about adjacent

structures and thus helps distinguish rhinoliths from other entities. Rhinoliths also can be seen incidentally in panoramic radiographs. Differential diagnosis should take into account benign tumors such as osteomas, bone sequestration and malignant tumors such as chondrosarcoma, osteosarcoma [9,12,13].

Treatment should include surgical removal as well as drug therapy for infection and symptomatic relief of pain and congestion. Surgical approach depends on the location and size of the mass. Most rhinoliths are usually removed endonasally. As in the cases described here. Large impacted rhinoliths can be removed piece meal with a variety of surgical instruments. Lithotripsy has also been used to debulk large rhinoliths [14]. If access remains restricted, a submucosal resection of the nasal septum and a bony turbinoplasty will allow for further exposure and will facilitate extraction. External approaches may be necessary in cases of giant rhinoliths. Irrigation and suction can help remove smaller fragments. Granulation tissue at the site of contact between a stone and the nasal mucosa can be cauterized with silver nitrate. Local infection is treated with appropriate antibiotics [7,10,13].

In conclusion, rhinolithiasis is an uncommon disease that may be left undiagnosed for many years and can be seen incidentally. Therefore, it is important that practitioners are aware of the possibility and examine radiographic images. In addition, CT examinations should be performed to determine the exact localization of the rhinolith and to make a differential diagnosis. Early referral by the primary care practitioner to obtain an Ear Nose Throat consult should be the rule to avoid misdiagnosis and complications.

Acknowledgement

Rinolitlerin minerolojik analiz ve 3D mikroskopik görüntülemesi Ege Üniversitesi Fen Fakültesi laboratuvarında yapılmıştır.

References

1. Ezsias A, Sugar AW. Rhinolith: An unusual case and an update. *Ann Otol Rhinol Laryngol* 1997;106:135-S.
2. Kharoubi S. Rhinolithiasis associated with septal perforation. A case report. *Acta Otorhinolaryngol Belg* 1998; 52: 241-5.
3. Yaşar H, Ozkul H, Verim A. Rhinolithiasis: a retrospective study and review of the literature. *Ear Nose Throat J* 2009; 88: 24
4. Orhan K, Kocycigit D, Kısınisci R, Paksoy CS. Rhinolithiasis: An uncommon entity of the nasal cavity. *Oral Surg Oral Med Oral Pathol Oral Radiol Endod* 2006; 101 (2): 28-32.
5. Appleton SS, Kimbrough RE, Engstrom HI. Rhinolithiasis: A review. *Oral surg Oral med Oral Pathol* 1988;65:693-8
6. Burbuk PK, Garstecka A, Betlelewski. Nasal foreign body in an adult. *Eur Arch Otorhinolaryngol* 2005;262:517-8.
7. Hadi U, Ghossaini S, Zaytoun G. Rhinolithiasis: A forgotten entity *Otolaryngol Head Neck Surg* 2002;126:48-52
8. Larrier D, Dhingra J. Radiology quiz case 1. Rhinolith. *Arch. Otolaryngol Head Neck Surg.* 2004;130:1340.
9. White SC, Pharoah MJ. Soft tissue calcification and ossification. *Oral Radiology - Principles and Interpretation*. 5th ed. Missouri: Mosby; p.607- 8.
10. Özdemir S, Görgülü O, Akbaş Y, et al. An unusual co-presentation of rhinolithiasis and squamous cell carcinoma in the nasal cavity. *J Craniomaxillofac Surg.* 2012 ;40(5):137-9.
11. Yılmaz S, Güven DG, Subaşı B, et al. A rhinolith surrounded by a nasal polyp. *J Craniofac Surg.* 2010 ;21(6):1954-5.
12. Gunduz K, Celenk P, Alkan A. Intranasal radiopacities: incidental panoramic radiograph findings. *Oral*

Radiol. 2010;26:41-45.

13. Shaw LCK. Rhinolith of endogenous origin: a rare entity. Surg Pract. 2007;11:48-50.

14. Mink A, Gati I, Szekely J. Nasolith removal with ultrasound lithotripsy. HNO 1991;39:116-17.