

CUTANEOUS LEIOMYOSARCOMA OF THE SUBMANDIBULAR REGION

SUBMANDİBULER BÖLGENİN KÜTANÖZ LEIOMYOSARKOMU

Baş Boyun Cerrahisi

Başvuru: 12.07.2018

Kabul: 08.10.2018

Yayın: 08.10.2018

Ali Bayram¹, Mehmet Yaşar², Yücel Tekin³, Serkan Altıparmak³

¹ Kayseri Eğitim ve Araştırma Hastanesi

² Kayseri ve Eğitim Araştırma Hastanesi

³ Kayseri Şehir Hastanesi

Özet

Yumuşak doku sarkomları, baş boyun bölgesindeki malign tümörlerin %1'ini oluşturmakta iken leiomyosarkom (LMS) bu bölgedeki tüm yumuşak doku sarkomlarının %1-4'üdür. Leiomyosarkom düz kas kökenli bir malign tümör olup yüzeysel (kütanöz ya da subkütan) ya da derin dokularda ortaya çıkabilir. Leiomyosarkomun kütanöz varyantı kıl foliküllerinin erector pili kaslarından gelişir. Burada 72 yaşındaki erkek hastada submandibuler bölgede 5 yıldır mevcut olan kütanöz LMS vakası sunulmuştur. Hastada tümör 1 cm cerrahi sınırla total olarak çıkarılmış ve 12 aydır nüks izlenmemiştir. Baş boyun bölgesi kütanöz LMS'u, nadir olması ve benign klinik görünümü sebebiyle, ileri hastalığa götürebilecek yanlış ya da gecikmiş tanıların neden olabilir. Baş boyun bölgesinde yakın cerrahi sınır ile total cerrahi eksizyon yeterli tedavi olabilse de, ile optimal cerrahi sınır miktarının netleştirilmesi için daha çok sayıda hastayı içeren başka çalışmalar gerekmektedir.

Anahtar kelimeler: Leiomyosarkom, Cilt Baş ve Boyun Neoplazmları

Abstract

Soft tissue sarcomas account for 1% of malignant tumors in the head and neck region, whereas leiomyosarcoma (LMS) constitutes 1-4% of all soft tissue sarcomas in this area. Leiomyosarcoma is a smooth muscle malignant tumor that can present either superficially (cutaneous or subcutaneous), or in the deeper tissues. A cutaneous variant of LMS is derived from erector pili muscles of hair follicles. Here, we present a cutaneous LMS of the submandibular region with a history of five years in a 72-year-old male patient. Total surgical removal of the tumor with a 1 cm surgical margin was performed and the patient is tumor free 12 months after the surgery. Due to the benign clinical aspect and rarity of cutaneous LMS in the head and neck region, a missed or delayed diagnosis of a tumor may lead to a more advanced disease. Total surgical removal of the tumor with a narrow surgical margin may be an adequate treatment in the head and neck area, however, further studies with a larger number of patients are required to clarify the optimal surgical margins.

Keywords: Leiomyosarcoma, Skin Head and Neck Neoplasms

Introduction

Leiomyosarcoma (LMS) is a smooth muscle malignant tumor that can present either superficially (cutaneous or subcutaneous), or in the deeper tissues. A cutaneous variant of LMS is derived from erector pili muscles of hair follicles [1]. Although superficial LMS may develop elsewhere in the body, the lower extremities are the most common region of tumor location [2]. Only 1-5% of LMSs have been reported in the head and neck area [3]. Here, we present a case of cutaneous LMS of the submandibular region in a male patient.

Case Report

Sorumlu Yazar: Ali Bayram, Kayseri Eğitim ve Araştırma Hastanesi
Sanayi Mah. Atatürk Bulvarı Hastane Cad. No:78 38010 Kocasinan
dralibayram@gmail.com

A 72-year-old male patient presented with a complaint of a painless submandibular mass that had been present for five years. The mass grew more rapidly in the last month. Head and neck examination revealed a 6x5x5 cm, non-tender tumor located in the left submandibular region (Figure 1).

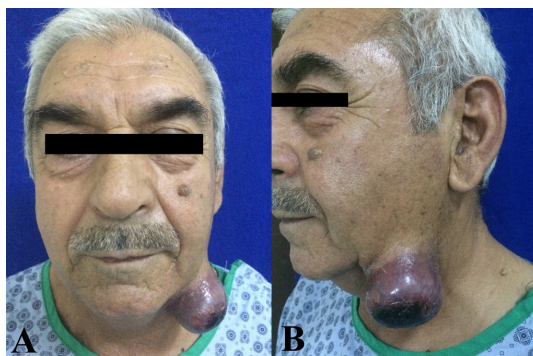

Figure 1

A 6x5x5 cm, non-tender tumor located in the left submandibular region. The skin overlying the lesion was ulcerated partially with a bluish-red color. A. Coronal view B. Sagittal view

The skin overlying the lesion was partially ulcerated with a bluish-red color. The tumor was mobile in the deeper plane but was adherent to the skin superficially. Contrast-enhanced computed tomography (CT) and magnetic resonance imaging (MRI) demonstrated a well-circumscribed, encapsulated heterogeneous lesion with prominent contrast enhancement that had extensions into the subcutaneous fat tissue (Figure 2).

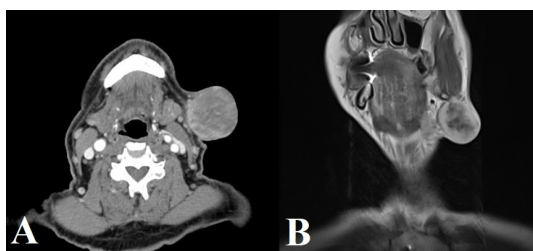


Figure 2

An axial CT (A) and a coronal contrast-enhanced MRI (B) revealed a well-circumscribed, encapsulated heterogeneous lesion with prominent contrast enhancement which had extensions into the subcutaneous fat tissue.

According to the radiological examinations, the tumor was not associated with the submandibular gland. Incisional biopsy was performed through the ulcerated overlying skin of the tumor and it was suggestive of a cutaneous LMS. Positron emission tomography (PET) showed no distant or neck metastases and total surgical removal of the tumor with overlying skin was performed with a 1 cm surgical margin under general anesthesia. Multiple frozen sections indicated clear surgical margins and the skin defect was reconstructed with a pectoralis major flap. Histopathological examination of the tumor revealed spindle cells with pleomorphic nuclei, cytologic atypia and high mitotic activity. Necrosis or angiolymphatic/perineural invasion was not present in the tumor. Immunohistochemical examination of the lesion showed diffuse positive staining for smooth-muscle actin (SMA) and vimentin, whereas focal staining was detected for desmin (Figure 3).

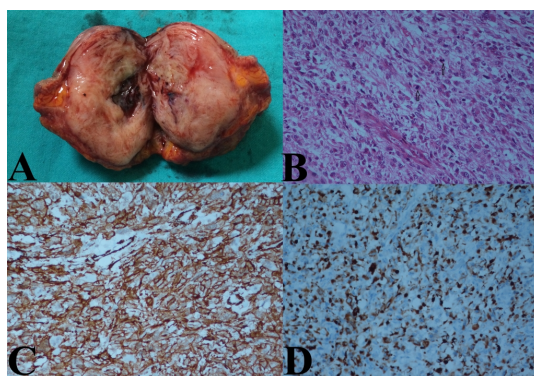


Figure 3

Macroscopic view of the tumor B. Pleomorphic spindle cells with atypical mitotic figures (arrows: atypical mitotic figures) (H&E; x200) C. Diffuse smooth muscle actin positivity (x200) D. Focal desmin positivity (x200)

The histopathological diagnosis of the lesion was compatible with cutaneous LMS of the submandibular region. According to the the Federation Nationale des Centres de Lutte Contre le Cancer (FNCLCC) grading system [4], which is based on tumor differentiation, mitotic rate/10 high-power fields, and degree of tumor necrosis, the present tumor had an intermediate grade. Adjuvant radiotherapy was recommended to the patient due to the poor prognostic indicators, including tumor size greater than 5 cm, advanced age and high mitotic activity, but the patient declined to receive any additional therapy and is tumor free according to physical and radiological examinations including MRI and PET 12 months after the surgery.

Discussion

Soft tissue sarcomas account for 1% of malignant tumors in the head and neck region, whereas LMSs constitute 1-4% of soft tissue sarcomas in this area [5]. In the head and neck area, cutaneous LMS is the most commonly encountered type, although it has also been reported in the larynx, oral cavity, paranasal sinuses and jaw [6]. Cutaneous LMS usually presents between the fifth and seventh decades of life with male predominance [7]. Clinical aspects of the tumor including a slowly enlarging, firm and painless mass with non-specific symptoms usually resemble benign tumoral conditions. Due to the rarity of LMS in the head and neck region and clinical findings similar to those in benign lesions, a missed or delayed diagnosis of the tumor may lead to a more advanced disease. In the present case report, the patient was a 72-year-old male with a history of the tumor for at least five years. The demographic data of the present case was compatible with the literature. The patient was admitted to the hospital with a 6x5x5 cm painless mass that was adherent to the overlying skin. He did not seek any medical aid during the five years for treatment of the tumor due to not having any symptoms, and the major concern of the patient was cosmetic during the hospital referral.

Trauma, irradiation, chemicals, and sunlight have been proposed as predisposing factors for cutaneous LMS in the literature [8]. Our patient had no history with respect to the predisposing factors. Differential diagnosis of LMS includes cysts, lipomas, fibromas, neurofibromas, dermatofibromas, carcinomas, persistent insect bites, granulomas and dermal nevi. Especially in elderly patients with cutaneous LMS in the head and neck, the tumor may clinically mimic basal cell carcinoma, squamous cell carcinoma, or pyogenic granuloma [8]. Histopathological characteristics of LMS can vary from well-differentiated to poorly differentiated tumors. Well-differentiated forms are composed of interlacing bundles of spindle tumor cells with cigar-shaped nuclei, whereas poorly differentiated tumors demonstrate anaplastic spindle cells with maloriented myofibrils and high mitotic count. The histologic grading system of FNCLCC has been reported to be associated with recurrence and metastasis [7]. Immunohistochemical expression of desmin, vimentin, SMA, reticulin and myoglobin can support the definitive diagnosis of LMS. Positive staining of vimentin and SMA is seen in all superficial LMS, however, desmin has

variable staining results with the presence of positive expression in approximately 60% of cases [9]. In the present case, the tumor was intermediate grade according to the FNCLCC grading system with diffuse positive staining for SMA and vimentin. Desmin expression was present focally in the tumor and these immunohistochemical findings were compatible with the literature.

Surgery is the most preferred treatment option for LMS, consisting of local excision with adequate surgical margins, however, optimal surgical margins have not been fully clarified to date in the literature. Previous reports recommended 2 to 5 cm surgical margins, whereas recent studies reported that surgical margins closer to 1 cm with adjuvant radiotherapy may also provide comparable survival rates [1]. Adjuvant radiotherapy is recommended for patients who have poor prognostic factors, including tumor size greater than 5 cm, high grade, high mitotic activity, advanced age, nodularity, subcutaneous extension and necrosis [1]. Systemic adjuvant chemotherapy was also shown to be effective in decreasing recurrence rates for resectable soft-tissue sarcomas, therefore chemotherapy may provide additional benefit in the treatment of head and neck LMS [10]. Elective neck dissection is not routinely performed due to the low incidence of node metastasis with cutaneous tumors. Head and neck LMS tends to be more aggressive than those in the uterus or gastrointestinal tract and has high regional recurrence rates, which constitute the major cause of death [11]. Thus, patients with head and neck LMS should have close long term follow-up after treatment. In the present case, the patient had some poor prognostic predictors, including a tumor size greater than 5 cm, high mitotic activity, advanced age and subcutaneous extension. After total surgical removal of the tumor with a 1 cm surgical margin, adjuvant radiotherapy was recommended to the patient due to the poor prognostic factors. However, the patient refused to receive adjuvant radiotherapy.

Cutaneous LMS has been reported to have a better prognosis than subcutaneous lesions, however, it has a remarkable local recurrence potential, which ranges between 14% and 50% [8]. Therefore cutaneous LMS necessitates close follow-up after treatment. The distant metastatic potential of cutaneous LMS is lower than that of subcutaneous tumors [8]. In the present case, no signs of local recurrence or distant metastases was detected according to physical and radiological examinations including MRI and PET one year after surgery although the patient received no adjuvant therapy. Similarly, Ko et al [2] reported a 3 cm sized cutaneous LMS of the preauricular area that was removed surgically with a 1 cm lateral margin. The patient had no locoregional recurrence despite the absence of any adjuvant therapy after a follow-up period of 15 months.

Cutaneous LMS is a variant of superficial LMS that can rarely be present in the head and neck region. Here, we present a case of cutaneous LMS of the submandibular region in a male patient that was treated surgically with a narrow surgical margin. The benign clinical aspect of cutaneous LMS may lead to a missed or delayed diagnosis of the tumor. A narrow surgical margin may be adequate in the removal of cutaneous LMS of the head and neck area, however, further studies with a larger number of patients are required to clarify the optimal surgical margins.

References

1. Workman AD, et al. Leiomyosarcoma of the head and neck: A 17-year single institution experience and review of the National Cancer Data Base. *Head Neck* 2018;40:756-62.
2. Ko YI, et al. Leiomyosarcoma of the Face. *Arch Craniofac Surg* 2014;15:36-9.
3. Tsutsumida A, et al. Management of superficial leiomyosarcoma: a retrospective study of 10 cases. *Plast Reconstr Surg* 2005;116:8-12.
4. M Trojani, et al. Soft-tissue sarcomas of adults; study of pathological prognostic variables and definition of a histopathological grading system. *Int J Cancer* 1984;33:37-42.
5. Eppsteiner RW, et al. Leiomyosarcoma of the head and neck: a population-based analysis. *Arch Otolaryngol Head Neck Surg* 2011;137:921-4.
6. Yadav J, et al. Head and neck leiomyosarcoma. *Indian J Otolaryngol Head Neck Surg* 2013;65:1-5.
7. Winchester DS, et al. Leiomyosarcoma of the skin: clinical, histopathologic, and prognostic factors that

- influence outcomes. *J Am Acad Dermatol* 2014;71:919-25.
8. De Giorgi V, et al. Superficial cutaneous leiomyosarcoma: a rare, misleading tumor. *Am J Clin Dermatol* 2008;9:185-7.
 9. Annest NM, et al. Cutaneous leiomyosarcoma: a tumor of the head and neck. *Dermatol Surg* 2007;33:628-33.
 10. Pervaiz N, et al. A systematic meta-analysis of randomized controlled trials of adjuvant chemotherapy for localized resectable soft tissue sarcoma. *Cancer* 2008;113:573-81.
 11. Montgomery E, Goldblum JR, Fisher C. Leiomyosarcoma of the head and neck: a clinicopathological study. *Histopathology* 2002;40:518-25.