

**INFRAHYOID VAGAL PARAGANGLIOMA: REPORT OF A RARE CASE**HYOID ALTI YERLEŞİMLİ VAGAL PARAGANGLIOMA: NADİR  
BİR VAKANIN SUNUMU

Başvuru: 04.02.2019

Kabul: 26.03.2019

Yayın: 26.03.2019

Baş Boyun Cerrahisi

**Kerem Kökoğlu<sup>1</sup>, Sedat Çağlı<sup>2</sup>, İmdat Yüce<sup>2</sup>, İrfan Kara<sup>3</sup>**<sup>1</sup> Kayseri Şehir Hastanesi<sup>2</sup> Erciyes Üniversitesi Tıp Fakültesi<sup>3</sup> Besni Devlet Hastanesi**Özet**

Paragangliomalar adrenal dışı paraganglia dokularından gelişen nöroendokrin tümörlerdir. Bu dokular nöral krestten gelişir ve otonom sinir sistemi ile ilişkilidir. Baş boyun paragangliomaları feokromasitomanın aksine genelde afonksiyoneldir. İlk semptom genellikle boyunda yavaş büyüyen kitledir. 42 yaşında kadın hasta böyle boyunda gittikçe büyüyen kitle şikayeti ile KBB kliniğine başvurdu. Muayenede boyun sağ tarafında 5 cm, yarı mobil ağrısız kitle izlendi. Ultrasonda karotis arkasında 33 mm, vasküler ve kistik alanlar içeren kitle izlendi. Operasyonda sağ vagal sinir kaynaklı 5 cm kitle lezyon izlendi. Vagal sinir feda edilerek kitle çıkarıldı. Patoloji paraganglioma ile uyumluydu. Hyoid altı yerleşimli bir vagal paraganlioma olgusu bu yazıda sunuldu. İngilizce literatürde, buna benzer daha önce sunulmuş 1 vaka vardır.

**Anahtar kelimeler:** vagus, nöral krest hyoid**Abstract**

Paragangliomas are neuroendocrine tumors which develop from extra-adrenal paraganglia tissues. This tissues derivate from neural crest and relate to autonomous nerve system. Head and neck paragangliomas are generally non-functioned unlike pheochromocytoma. The first symptom is slow-growing mass in neck usually. A 42-year-old woman was admitted to otolaryngology clinic with the complaint of neck mass which was slow-growing. There was a 5 cm, painless, semi-mobile mass in her right neck. There was no other pathological finding. It was a 33 mm mass behind the carotis in ultrasound examination. It was hypervascular and including cystic areas. There was a 5 cm tumor which developed from the right vagal nerve in the operation. Vagal nerve was sacrificed to remove tumor. Specimen was consistent with paraganglioma. An unusual infrahyoid vagal paraganglioma case was presented in this paper. There is only one report about such a disease before in English literature.

**Keywords:** vagus, neural crest hyoid**Introduction**

Paraganglioma (PG) is a neuroendocrin tumor which develops extra-adrenal paraganglia cells. It is related to sympathetic or parasympathetic system. Head and neck PG (HNPG) usually develops parasympathetic system. PG is called according to its developed area; carotid, jugular, tympanic or vagal. Chemodectoma and glomus terms were used before, but paraganglioma is preferred now [1]. 1-3 % of HNPG secrete catecholamins [2]. They usually have multipl endocrine neoplasia (MEN) syndrome. 40 % of familial form and 10 % of sporadic form could be multipl [3].

The most common symptom of HNPG is painless, slow-growing mass in neck. HNPG is more common in women unlike other PGs [1]. 60 % of HNPG is related to carotid body. HNPG which develops from vagal nerve is under 5 %. [4]. Vagal PG is largely close to skull base and cranial nerves are effected more [5]. Although vagal PG could develop from everywhere of vagus nerve theoritically, it develops from ganglion nodosum generally [6]. A 42-year old woman who had infrahyoid vagal PG is presented in this paper.

Sorumlu Yazar: Kerem Kökoğlu, Kayseri Şehir Hastanesi  
Kayseri  
dr.kokoglu@gmail.com

## Case Report

A 42-year old women was admitted to clinic with the complaint of slow-growing neck lump. She had the lump for 6 years. She denied smoking or alcohol abuse, B symptoms and flushing attacks, contact of cats or rodents. She had no chronic disease. There was a 5 cm, semi-mobil, painless neck mass in the right supraclavicular area in her physical examination. Vocal cord movements were normal bilaterally. There was no pathologic finding in the other examination. There was a 33x29 mm hypervascular hypoechoic mass in the right neck with cystic areas inferiorly and medially in her ultrasound (US) examination. The mass was behind the carotid arter and jugular vein. Fine needle aspiration biopsy (FNAB) could not be done because of its hypervascularity feature. There was no pathological condition about thyroid and lymph nodes. There was a 35x31x53 mm, heterogenous contrasted mass in magnetic resonance imagination (MRI) (Images 1A-1B). A neck exploration, excision and frozen section were planned for the treatment of patient. A mass which develops from vagal nerve was seen during operation. It could not be dissected from vagal nerve. Therefore, vagal nerve was sacrificed. She had hoarseness postoperatively, but she could swallow without aspiration. Her voice was normal after 6th month of surgery. 123-I metaiodobenzylguanidine scintigraphy (123I-MIBG) was done because of possibility of multipl disease and no disease was seen (Image 1C). Biopsy result was paraganglioma (Image 1D). There was no recurrens in a 2-year period.

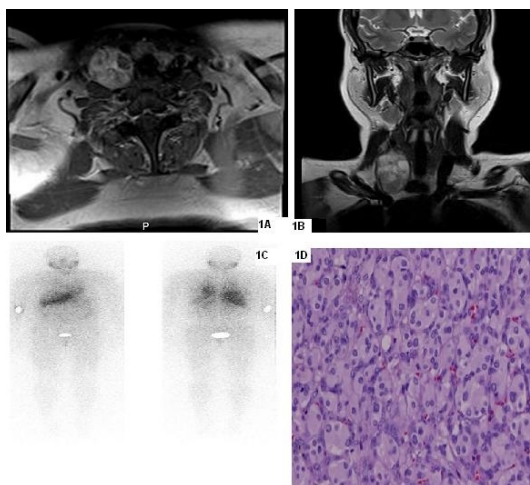


Image 1A: Axial section of MRI shows heterogenous contrasted mass on the right.  
 Image 1B: Coronal section of MRI shows the mass.  
 Image 1C: 123I-MIBG Scintigraphy shows no disease.  
 Image 1D: Zellballen bodies are seen in pathological examination microscopically.

**Figure 1**  
 Images

## Discussion

PG is 0.6 % of head and neck tumors [7]. HNPG is usually related to parasympathetic system and does not secrete catecholamines [1]. Vagal PG is common in middle-aged women. Patients exhibit slow-growing neck mass largely. When PG causes cranial nerve paralysis, they can be admitted with cranial neuropathy symptoms. Although it is usually negative, urinary catecholamin examination must be done because of possibility of associated pheochromocytoma or other PG [8]. Urinary catecholamin test was not done in the patient because of its unusual location.

Computed tomography (CT) and MRI angiography are useful in the diagnosis. Vagal PG pushes forward external and internal carotid arteries. They are highly contrasted tumors. 123I-MIBG scintigraphy can be done for multiple disease [9]. Because of its atypical location and heterogenous contrasted view, PG was not thought in pre-diagnosis.

Treatment of vagal PG is surgical. Vagal nerve is sacrificed in almost case [10]. Although some examiners offer vocal cord medialization in the same seans, it is not accepted generally. If there is 10th and 12th nerve paralysis, aspiration risk is more [6]. There are some reports about preoperative embolization is useful for intraoperative bleeding [10].

Although vagal PG could develop from everywhere of vagus nerve theoretically, it develops from ganglion nodosum generally [6]. Infrahyoid vagal PG is very rare and there is only one case about it in the English literature. Saito et al. reported a infrahyoid vagal PG which was seen catecholamin crisis during operation [11].

A very rare case, infrahyoid vagal PG, is presented in the paper. Sharing such this case enriches the literature and increases awareness. Vagal paraganglioma must be considered in pre-diagnosis especially in the patients have highly contrasted tumor behind the carotid artery.

## References

1. Pellitteri PK, Rinaldo A, Myssiorek D, Gary Jackson C, Bradley PJ, Devaney KO, et al. Paragangliomas of the head and neck. *Oral Oncol* 2004;40(6):563-75.
2. Manolidis S, Shohet JA, Jackson CG, Glasscock ME, 3rd. Malignant glomus tumors. *Laryngoscope* 1999;109(1):30-4.
3. Bikhazi PH, Roeder E, Attaie A, Lalwani AK. Familial paragangliomas: the emerging impact of molecular genetics on evaluation and management. *Am J Otol* 1999;20(5):639-43.
4. Sniezek JC, Netterville JL, Sabri AN. Vagal paragangliomas. *Otolaryngol Clin North Am* 2001;34(5):925-39, vi.
5. Biller HF, Lawson W, Som P, Rosenfeld R. Glomus vagale tumors. *Ann Otol Rhinol Laryngol* 1989;98(1 Pt 1):21-6.
6. Eriksen C, Girdhar-Gopal H, Lowry LD. Vagal paragangliomas: a report of nine cases. *Am J Otolaryngol* 1991;12(5):278-87.
7. Lozano FS, Gomez JL, Mondillo MC, Gonzalez-Porras JR, Gonzalez-Sarmiento R, Munoz A. Surgery of vagal paragangliomas: six patients and review of literature. *Surg Oncol* 2008;17(4):281-7.
8. Hamersley ER, Barrows A, Perez A, Schroeder A, Castle JT. Malignant Vagal Paraganglioma. *Head and neck pathology* 2015:1-5.
9. Offergeld C, Brase C, Yaremchuk S, Mader I, Rischke HC, Glasker S, et al. Head and neck paragangliomas: clinical and molecular genetic classification. *Clinics (Sao Paulo)* 2012;67 Suppl 1:19-28.
10. Miller RB, Boon MS, Atkins JP, Lowry LD. Vagal paraganglioma: the Jefferson experience. *Otolaryngol Head Neck Surg* 2000;122(4):482-7.
11. Saito Y, Mitani H, Oguri C, Shinbashi W, Yonekawa H, Kawabata K. Occult functioning vagal paraganglioma in the infrahyoid carotid sheath. *Auris Nasus Larynx* 2013;40(3):330-333.

## Presented at

The Turkish National Otolaryngology - Head and Neck Congress, 2015 Antalya - Turkey