

SIMULTANEOUS SURGERY FOR SQUAMOUS CELL CARCINOMA OF THE LARYNX AND ATHEROSCLEROTIC CAROTID ARTERY DISEASE

LARENKS YASSI HÜCRELİ KARSİNOMU VE ATEROSKLEROTİK
KAROTİS ARTER HASTALIĞININ EŞ ZAMANLI CERRAHİSİ
Baş Boyun Cerrahisi

Başvuru: 04.06.2015
Kabul: 27.07.2015
Yayın: 27.07.2015

Ali Bayram¹, Altan Kaya¹, İbrahim Hıra², Ali Koç², İbrahim Özcan²

¹ Kayseri Eğitim ve Araştırma Hastanesi
² Kayseri ve Eğitim Araştırma Hastanesi

Özet

Elli dokuz yaşındaki erkek hastada, larenks yassı hücreli karsinomu ve ciddi stenotik aterosklerotik arter hastalığı vakasını sunmaktayız. Hasta eş zamanlı olarak, herhangi bir komplikasyon görülmesizin, karotis endarterektomi ve onkolojik cerrahi geçirmiştir. Larenks yassı hücreli karsinomu için onkolojik cerrahi ve karotis endarterektomi, seçilmiş hastalarda, aynı seansta ek morbidite olmadan yapılabilir.

Anahtar kelimeler: Larenks, Karsinom Yassı hücreli Endarterektomi Karotis

Abstract

We describe a case of larynx squamous cell carcinoma (SCC) with severe stenotic atherosclerotic carotid artery disease (ASCAD) in a 59-year-old male patient. The patient underwent simultaneous carotid endarterectomy and oncologic surgery without any complications. Oncologic surgery for larynx SCC and carotid endarterectomy may be performed simultaneously without additional morbidity at the same procedure in selected patients.

Keywords: Larynx, Carcinoma Squamous cell Endarterectomy Carotid

Introduction

Atherosclerotic carotid artery disease (ASCAD) and squamous cell carcinoma of the head and neck (HNSCC) can be simultaneously present, having identical risk factors including age, sex, smoking, alcoholism, irradiation, and occupation [1]. Surgery and/or irradiation for HNSCC and cancer-associated hypercoagulation can also contribute to cerebrovascular accidents and ASCAD during treatment of the primary tumor [2,3-6]. Here, we describe a case of larynx squamous cell carcinoma (SCC) with severe stenotic ASCAD who underwent simultaneous carotid endarterectomy and oncologic surgery.

Case Report

A 59-year-old male patient presented with a history of intermittent hoarseness persisting for about a year. In the last few months, he had progressive dyspnea with mild dysphagia. He had an 80 pack-year history of smoking with no alcohol consumption. Endoscopic examination of the larynx revealed a lesion of the left true vocal cord extending to the interarytenoid and subglottic area with a left vocal cord immobility (Figure 1a). There were no palpable lymph nodes in the neck. Contrast-enhanced larynx CT of the patient demonstrated a tumoral lesion of the left subglottic area extending through the left vocal cord with anterior commissure invasion (Figure 1b).

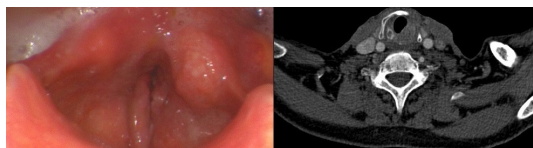


Figure 1

A. Flexible laryngoscopic image of the patient. B. Contrast-enhanced larynx CT of the patient.

There was also severe stenosis of the left internal carotid artery (Figure 2a). Doppler ultrasonography and 3D contrast-enhanced MR angiography (Figure 2b) revealed a focal severe stenosis (70-99%, according to the NASCET criteria [9]) of the left internal carotid artery, located one centimeter above the carotid bifurcation. The patient was free of any symptoms regarding stenosis of the carotid artery.

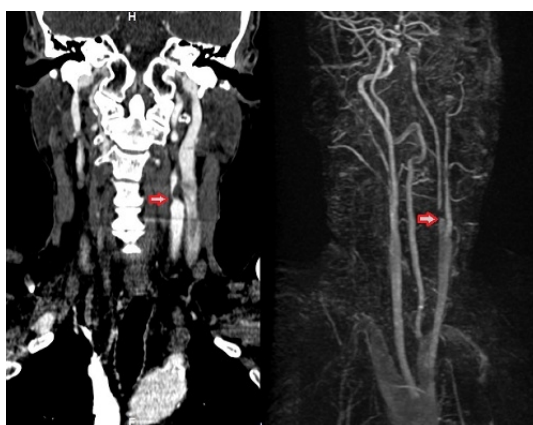


Figure 2

A. Coronal contrast-enhanced CT of the neck. B. 3D contrast-enhanced MR angiography. A focal severe stenosis of the left internal carotid artery (red arrows).

Direct laryngoscopy and biopsy were performed after securing the airway with tracheotomy. Direct laryngoscopy demonstrated a tumoral lesion of the left subglottic area, invading the left true vocal cord, ventricle and interarytenoid area. The subglottic extension of the tumor was more than one centimeter and histopathological examination of the punch biopsies taken from the left vocal cord, subglottic and interarytenoid area revealed SCC of the larynx. After consultation with a vascular surgeon, total laryngectomy (Figure 3a), bilateral lateral neck dissection and simultaneous carotid endarterectomy (Figure 3b) were performed on the patient at the same procedure. Total laryngectomy was performed to the patient due to involvement of the interarytenoid area with extensive left subglottic tumoral disease.

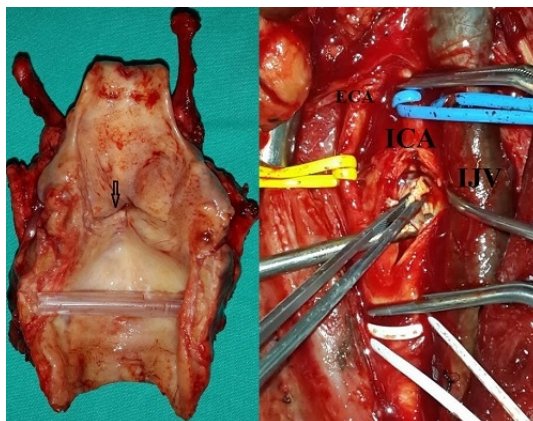


Figure 3

A. Total laryngectomy specimen (black arrow showing tumoral lesion) B. Carotid endarterectomy (ECA: external carotid artery, ICA: internal carotid artery, IJV: internal jugular vein).

The postoperative course was uneventful but histopathological examination revealed a metastatic lymph node of level IV on the left side of the neck and thyroid cartilage invasion. The patient received adjuvant radiotherapy to the primary tumor bed, peristomal area and bilateral level II-VI lymph nodes. A Doppler study following the completion of adjuvant radiotherapy revealed a patent carotid artery and close follow-up of the patient is ongoing.

Discussion

ASCAD is a serious condition that causes a risk of stroke with stenosis of the carotid artery due to the progression of atherosclerosis with time. The risk of stroke is correlated with the percentage of carotid stenosis [1]. The prevalence of hemodynamically significant carotid stenosis (>50%) in the general population is between 1.2% and 4.2% [7,8]. The treatment of advanced ASCAD can be done either medically or surgically. Medical treatment includes anticoagulation therapy, diet and hyperlipidemia control. Surgical therapy involves a carotid endarterectomy. The North American Symptomatic Carotid Endarterectomy Trial revealed that surgical treatment offers better results than medical therapy for symptomatic stenosis greater than 70%, with an absolute reduction in stroke risk of 9% versus 26% [9]. On the other hand, treatment of asymptomatic ASCAD is not very clear. The Asymptomatic Carotid Atherosclerosis Study demonstrated a reduction of 1% in morbidity and mortality with surgical treatment in patients with asymptomatic carotid stenosis of 60% or greater [10], and therefore many clinicians have advocated a watch-and-wait approach [5].

ASCAD and HNSCC have similar risk factors that provide a major concern in the co-existence of these pathologies. Age, sex, smoking, alcoholism, irradiation, and occupation are identical risk factors of the two pathologies [1]. Although similar risk factors may contribute to the co-existence of ASCAD and HNSCC, Cote et al [1] reported that the rate of carotid disease in patients with HNSCC was similar to that found in the general population. Nevertheless, there are very few reports in the literature regarding combined oncologic resection and carotid endarterectomy in patients with HNSCC. Rechtweg et al [11] reported three patients who underwent neck dissection for HNSCC and simultaneous carotid endarterectomy. They concluded that endarterectomy for severe carotid stenosis can be performed simultaneously with treatment of HNSCC with no increase in morbidity. In their series of 11 patients, Kroeker et al [12] found that the collaboration of head and neck surgeons with vascular surgeons provides the patient with oncologic resection and revascularization with a low perioperative risk of stroke. In the present case, simultaneous oncologic surgery and carotid endarterectomy were achieved without any complication in the patient with larynx SCC and severe stenotic ASCAD. The excellent visualization of the carotid artery during the neck dissection facilitated the removal of atherosclerotic disease localized in the internal carotid

artery with minimal surgical risk by the vascular surgeon. Patients with simultaneous HNSCC and severe stenotic ASCAD may benefit from combined oncologic surgery and carotid endarterectomy in the same procedure to prevent cerebrovascular disease that may occur peri- or postoperatively owing to the untreated ASCAD. Nevertheless, larger series with more participants are required to definitely establish the safety and potential risks of the combined procedure.

Conclusion

Oncologic surgery for larynx SCC and carotid endarterectomy may be performed simultaneously without additional morbidity at the same procedure in selected patients.

Acknowledgement

The authors thank Dr. Alper Sami Kunt from the Department of Cardiovascular Surgery, Kayseri Training and Research Hospital, for his assistance in the procedure of carotid endarterectomy.

References

1. Cote CR, et al. The prevalence of occult carotid artery stenosis in patients with head and neck squamous cell carcinoma. *Laryngoscope* 2001;111:2214-7.
2. Nosan DK, Gomez CR, Maves MD. Perioperative stroke in patients undergoing head and neck surgery. *Ann Otol Rhinol Laryngol* 1993;102:717-23.
3. Parikh S, Cohen JR. Perioperative stroke after general surgical procedures. *N Y State J Med* 1993;93:162-5.
4. Citardi MJ, et al. Management of carotid artery rupture by monitored endovascular therapeutic occlusion (1988-1994). *Laryngoscope* 1995;105:1086-92
5. Sprung J, et al. Asymptomatic carotid stenosis and stroke during neck surgery. *Otolaryngol Head Neck Surg* 1996;115:568-72.
6. Autret A, et al. Stroke risk in patients with carotid stenosis. *Lancet* 1987;18:888-90.
7. Kiechl S. Quantitative assessment of carotid atherosclerosis in a healthy population. *Neuroepidemiology* 1994;13:314-7.
8. Paivansalo M, et al. Prevalence of carotid atherosclerosis in middle-aged hypertensive and control subjects. A cross-sectional systematic study with duplex ultrasound. *J Hypertens* 1996;14:1433-9.
9. North American Symptomatic Carotid Endarterectomy Trial (NASCET) Collaborators. Beneficial effect of carotid endarterectomy in symptomatic patients with high grade carotid stenosis. *N Engl J Med* 1991;325:445-53.
10. Executive Committee for the Asymptomatic Carotid Atherosclerosis Study. Endarterectomy for asymptomatic carotid artery stenosis. *JAMA* 1995;273:1421-8.
11. Rechtweg J, et al. Neck dissection with simultaneous carotid endarterectomy. *Laryngoscope* 1998;108:1150-3.
12. Kroeker TR, O'Brien JC. Outcomes of combined oncologic resection and carotid endarterectomy in patients with head and neck cancer. *Head Neck* 2013;35:E167-70.