

SPINAL ACCESSORY NERVE PASSING THROUGH THE FENESTRATED INTERNAL JUGULAR VEIN

FENESTRASYON GÖSTEREN İNTERNAL JUGULER VEN İÇİNDEN
GEÇEN SPİNAL AKSESUAR SİNİR
Baş Boyun Cerrahisi

Başvuru: 07.06.2015
Kabul: 23.11.2015
Yayın: 23.11.2015

Onur İsmi¹, Övgü Cinpolat², Göktekin Tenekeci¹, Alper Sarı¹, Yusuf Vayisoğlu¹

¹ Mersin Üniversitesi Tıp Fakültesi
² Gaziantep Şehit Kamil Hastanesi

Özet

Boyunda level II'deki cerrahi müdahaleler sırasında en önemli anatomik yapı spinal aksesuar sinirdir. Nörovasküler komplikasyonları önlemek için bu seviyede spinal aksesuar sinirle internal juguler ven arasındaki anatomik ilişki çok önemlidir. Digastrik kasın arka karnı hizasında sinir çoğunlukla venin lateral(anterior)inden ya da medial(posterior)undan geçer. Literatürde spinal aksesuar sinirin fenestre internal juguler ven içinden geçtiği çok az olgu mevcuttur. Bu olguların çoğu kadavra diseksiyonu ya da bilinen üst aerodigestif sistem malignitesi olan hastalarda boyun diseksiyonu sonuçlarıdır. Bu olgu sunumunda ilk kez level Iİye kadar inen parotis bölgesi lenfanjiomlu 4 yaşında hastada spinal aksesuar sinirin fenestre internal juguler ven içinden geçtiği anatomik varyasyonu sunduk. spinal aksesuar sinirle internal juguler ven arasındaki anatomik varyasyonlar klinik önemleriyle birlikte güncel literatür bilgileri ışığında sunulmuştur.

Anahtar kelimeler: Spinal aksesuar sinir, İnternal juguler ven Fenestrasyon Seviye II

Abstract

During surgical intervention dealing with level II; the most important anatomical structure is spinal accessory nerve. The anatomic relationship between spinal accessory nerve with internal jugular vein in this level is very important for precluding neurovascular complications. The nerve mostly passes lateral(anterior) or medial(posterior) to internal jugular vein at the level of medial aspect of posterior belly of digastric muscle. Very few cases of spinal accessory nerve passing through a fenestrated internal jugular vein are published. Most of these cases are cadavers or neck dissection results of a known aerodigestive malignancy. We presented the first case of 4 years old patient with a parotid region lymphangioma descending to level II with a spinal accessory nerve passing through the fenestrated internal jugular vein. Anatomic variations between spinal accessory nerve and internal jugular vein are discussed with their clinical impacts under the light of current literature.

Keywords: Spinal accessory nerve, Internal jugular vein Fenestrated variation Level II

Introduction

Level II is the regional lymph node group descending from skull base to bifurcation of carotid artery or the hyoid bone. Anterior limit of this region is sternohyoid muscle and posterior limit is posterior border of sternocleidomastoid muscle. The most important anatomical structure in this region is spinal accessory nerve (SAN). Lymph nodes anterior to SAN are designated as level IIA, whereas lymph nodes posterior to this nerve belong to level IIB [1]. During surgical intervention in this region such as a neck dissection; anatomical course of SAN must be known. Although variable anatomic relationships between the nerve and internal jugular vein (IJV) exist in the literature, SAN mostly passes anterior(lateral) to IJV and less commonly posterior (medial) to it [2-4]. A few cases of SAN passing through a fenestrated IJV are also published [2-8]. Most of these were neck dissections for a known malignancy or cadaveric studies. We presented the first case of SAN passing through a fenestrated IJV in a pediatric patient during neck exploration of level II for a benign neck mass lymphangioma (LAM).

Case Report

Four years old otherwise healthy girl was consulted to our Mersin University Otorhinolaryngology department from Plastic and Reconstructive surgery for mass in the right upper neck. In her medical history the mass was learned to be present in the newborn period and gradually increased in size descending to neck region. In her physical examination; a 4 x 4 cm. tender mass starting from preauricular region descending to right level II was palpated. On her neck and parotid computerized tomography; an irregular shaped mass starting from preauricular region descending to thyroid cartilage level with involvement of the right parotid gland was seen with the preliminary diagnosis of lymphangioma. Superficial parotidectomy with neck exploration was performed under general anesthesia. During surgical intervention in the upper neck posterior belly of the digastric muscle was extracted to be able to totally excise the mass in the level II. After extraction of the muscle, an unusual anatomic relationship between SAN and IJV was seen. The IJV had a fenestration nearly 1 cm. above the carotid bifurcation. The nerve transmitted through the fenestrated IJV. (Figure 1)

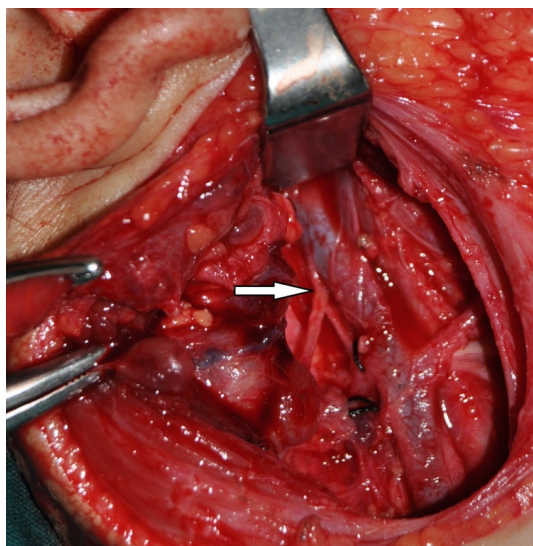


Figure 1

Intraoperative appearance of the patient was shown.(White arrow shows the right spinal accessory nerve passing through the fenestrated internal jugular vein)

Superficial parotidectomy was performed with neck exploration and the mass was totally excised. Postoperative pathological analysis of the specimen resulted as lymphangioma. Postoperative period was uneventful without complication, there was no facial weakness or shoulder pain and the patient was discharged on the fourth day.

Discussion

Spinal accessory nerve is the XIth cranial nerve which exists the cranium through jugular foramen with other nerves glossopharyngeus and vagus. It passes mostly lateral or medial to IJV before giving rise to motor innervation of sternocleidomastoid and trapezius muscles. It courses neck level II in a superoinferior and medial to lateral direction dividing the space into two as level IIA and IIB [3]. It has several anatomic connections with other cervical and cranial nerves, the term spinal accessory nerve plexus was used to describe this condition [9].

During surgical manipulation in level II, traumatic injury to SAN can cause shoulder syndrome which is characterized by shoulder pain, limited movement and dropping of the shoulder which has adverse effects on

quality of life of the patients [3]. To avoid shoulder syndrome and vascular damage to IJV, anatomic relationships and variations between SAN and IJV must be well known. There are great variations among authors for anatomic relationship of SAN and IJV. In the series of Lee et al. SAN passes IJV ventrally (anterior) in 39.8 % of cases, dorsally (posterior) in 57.4 % of cases. There was only 2.8 % of cases SAN passes through the fenestrated IJV like our case [3]. For Taylor et al. lateral(anterior) crossing was 95.6% and medial (posterior) crossing was 2.8%. SAN passing through the fenestrated IJV was only 0.9 % of cases [2]. For Saman et al. with cadaver series SAN crossed IJV anteriorly in 80 %, posteriorly in 19 % of cases. Only one case (1%) was present with SAN piercing the bifurcated IJV [8]. Recently Hinsley and Hartig presented a neck dissection series with a dominant lateral crossing type.(96%) SAN crossing through the fenestrated IJV was only 1 % in their series. [4] Levy et al. studied 123 neck dissection patients with addition to 5 cadavers, none of them showed a SAN passing through the fenestrated IJV [10] The articles concerning the anatomic relationship between SAN and IJV were summarized in table 1.

The great variations regarding the ratios of anatomic relationship between SAN and IJV can be explained by study population and level of dissection. In the cadavers the tissues are shrunken and IJV may be collapsed which modifies the relationship with SAN. This condition may explain a higher incidence of SAN medial (posterior) crossing to IJV at level II in cadaver studies [10]. Also if the dissection is not carried out high enough at the level of medial aspect of digastric muscle, the nerve may falsely seem to lie posterior to the vein which also contributes to false positive result of a medially crossing nerve [2].

The terms fenestration and duplication were used interchangeably by authors for describing the accessory lumen of IJV. Downie et al. suggested a new classification, they argued that the term duplication should be used for cases of IJV joining the subclavian vein as separate two veins in an up-side-down Y pattern. They also mentioned that the term fenestration should be used for cases who have IJV branching into two veins for some distance, the veins refuse and enter the subclavian vein as a single vein like our case [11]. When a fenestrated IJV exists, mostly SAN passes through the fenestration [5]. Rarely SAN can pass medial (posterior) part of the fenestrated IJV [12].

The exact cause of a SAN passing through the fenestrated IJV is not known, but mostly an embryological base is suspected. Three hypotheses including vascular, neural and bony exist, vascular one is the most likely cause. According to vascular theory; embryologically nerves generally emerge after the formation of vessels. In the embryo, origin of the IJV is the precardinal veins that drain the blood from cranium. Inadequate condensation of embryologic capillary plexus which develops posterior to precardinal veins may lead to a duplication of IJV. Normally two veins emerge from capillary plexus, lateral and medial one. During embryological development one of them disappears. If the medial one disappears the lateral one form the IJV and so SAN passes from the medial aspect of the IJV, if the lateral one disappears SAN passes from the lateral part of the IJV. Persistence of the capillary plexus gives rise to fenestrated or duplicated IJV with a SAN passing through it [5,7] Although vascular theory is mostly accepted by authors; this theory is not enough for explaining the case reported by Alaani et al. [12] In their case report there was a duplication in the IJV but SAN passed from the posterior part of the duplication not through it. The final morphology of this vascular system is determined by multiple factors such as genetics, hemodynamics, growth and neural factors. An insult including at least one of these in the embryological development period may lead to alterations in the morphology of IJV and the relationship between SAN and IJV [11].

Lymphangiomas are low-flow vascular malformations of the lymphatic channels. Since head and neck region consists of large number of lymphatics, they are mostly (75%) seen in this region. Macrocystic ones are greater than two cm. in diameter. They are mostly seen as multilocular cystic spaces lateral to parotid or submandibular gland like in our case [13,14]. The exact cause of LAM is not known, but an embryological failure in connection of lymphatics to associated venous system is suspected [14]. The malformation may also include associated venous system with lymphatics, called as venolymphatic malformation [13]. For our case macrocystic LAM was seen at the same side of SAN passing through the IJV. An embryological insult may be the reason of fenestrated IJV and interruption in connection of parotid region lymphatics to this vein may be the reason of concomitant macrocystic

parotid region LAM for our case.

When cadaveric studies are excluded, we presented the 18th case of SAN passing through the fenestrated IJV according to Downie classification in English literature. Most of the previously reported cases were patients undergoing neck dissections due to a known aerodigestive malignancy. Our case was a four years old pediatric patient with a benign neck mass lymphangioma. (Table 1)

Table 1. Articles concerning the anatomic relationship between SAN and IJV in the level II.

AUTHOR	PUBLISHED YEAR	STUDY POPULATION	NUMBER OF CASES	SAN LATERAL TO IJV	PASSING SAN MEDIAL TO IJV	SAN PASSING THROUGH THE FENESTRATED IJV
Kiemer et al. ¹⁰	2000	Cadavers	43	24(56%)	19(44%)	0
Takay et al. ⁶	2001	Neck dissections+cadavers	133	132(99.25%)	1(0.75%)	0
Gardiner et al. ⁶	2002	Neck dissection				1 case
Prades et al. ⁷	2002	Neck dissections				3 cases
Hayak et al. ⁹	2006	Cadaver				1 case
Iseri et al. ⁹	2006	Neck dissection				1 case
Lee et al. ³	2009	Neck dissections	181	72(39.8%)	104(57.4%)	5(2.8%)
Hinsley et al. ⁴	2010	Neck dissections	116	112(96%)	3(3%)	1(1%)
Ozgurk et al. ¹¹	2010	Cadaver				1 case
Saman et al. ⁸	2011	Cadavers	84	87(80%)	16(19%)	1(1%)
Hashimoto et al. ⁵	2012	Neck dissections				4 cases
Taylor et al. ²	2013	Neck dissections+neck explorations	207	188(95.7%)	6(2.8%)	2(0.9%)
Ismi et al.		4 years old pediatric patient				1 case

¹⁰Presented case

IJV: Internal Jugular Vein, SAN: Spinal Accessory Nerve.

Table 1

Articles concerning the anatomic relationship between SAN and IJV in the level II.

As a conclusion; spinal accessory nerve passing through the fenestrated internal jugular vein is a rare anomaly. Since the cause of this variation is mostly accepted to be an embryological insult, it can also be seen in pediatric patients accompanying congenital vascular malformations. To prevent hazardous neurovascular complications, this rare anomaly must also be kept in mind during surgical intervention in level II of pediatric patients with congenital vascular malformations like lymphangiomas.

References

- Shah J, Patel S, Singh B. 2012. Head and neck surgery and oncology(4th ed.). Cervical Lymph nodes. Elsevier: Philadelphia. p 426-70.
- Taylor CB, Boone JL, Schmalbach CE, Miller FR. Intraoperative relationship of the spinal accessory nerve to the internal jugular vein: variation from cadaver studies. *Am J Otolaryngol.* 2013;4:527-9.
- Lee SH, Lee JK, Jin SM, Kim JH, Park IS, Chu HR, Ahn HY, Rho YS. Anatomical variations of the spinal accessory nerve and its relevance to level IIB lymph nodes. *Otolaryngol Head Neck Surg.* 2009; 141:639-44.
- Hinsley ML, Hartig GK. Anatomic relationship between the spinal accessory nerve and internal jugular vein in the upper neck. *Otolaryngol Head Neck Surg.* 2010; 143:239-41.
- Hashimoto Y, Otsuki N, Morimoto K, Saito M, Nibu K. Four cases of spinal accessory nerve passing through the fenestrated internal jugular vein. *Surg Radiol Anat.* 2012; 34:373-5.
- Gardiner KJ, Irvine BW, Murray A. Anomalous relationship of the spinal accessory nerve to the internal jugular vein. *Clin Anat.* 2002; 15:62-3.
- Prades JM, Timoshenko A, Dumollard JM, Durand M, Merzougui N, Martin C. High duplication of the internal jugular vein: clinical incidence in the adult and surgical consequences, a report of three clinical cases. *Surg Radiol Anat.* 2002; 24:129-32.
- Saman M, Etebari P, Pakdaman MN, Urken ML. Anatomic relationship between the spinal accessory nerve and the jugular vein: a cadaveric study. *Surg Radiol Anat.* 2011; 33:175-9.
- Iseri M, Ustundag E, Aydın O. A rare anatomical variation of the spinal accessory nerve. *J Laryngol Otol.* 2007; 121:277-8.
- Lévy D, Vacher C, Lezy JP. Relations of the accessory nerve with the internal jugular vein: surgical implications in cervical lymph node clearances. *Surg Radiol Anat.* 2001; 23:155-7.
- Downie SA, Schalop L, Mazurek JN, Savitch G, Lelonek GJ, Olson TR. Bilateral duplicated internal

- jugular veins: Case study and literature review. *Clin Anat.* 2007; 20:260-6.
12. Alaani A, Webster K, Pracy JP. Duplication of internal jugular vein and relation to the spinal accessory nerve. *Br J Oral Maxillofac Surg.* 2005; 43:528-31.
 13. Hoff SR, Rastatter JC, Richter GT. Head and neck vascular lesions. *Otolaryngol Clin N Am.* 2015; 48:29-45.
 14. Manning SC, Perkins J. Lymphatic malformations. *Curr Opin Otolaryngol Head Neck Surg.* 2013; 21:571-5.
 15. Kierner AC, Zelenka I, Heller S, Burian M. Surgical anatomy of the spinal accessory nerve and the trapezius branches of cervical plexus. *Arch Surg.* 2000; 135:1428-31.
 16. Nayak BS. Surgically important variations of the jugular veins. *Clin Anat.* 2006; 19:544-6.
 17. Ozturk NC, Talas DU. Fenestration of internal jugular vein and relation to spinal accessory nerve: Case report and review of the literature. *Clin Anat.* 2010; 23:883-4.