

# A RARE CASE REPORT: METHICILLIN-SENSITIVE STAPHYLOCOCCUS AUREUS LIP ABSCESS

NADİR BİR OLGU SUNUMU: METİSİLİN-DUYARLI STAPHYLOCOCCUS AUREUS İLİŞKİLİ DUDAK APSESİ  
Baş Boyun Cerrahisi

Başvuru: 11.09.2021  
Kabul: 01.04.2022  
Yayın: 01.04.2022

**Buğra Subaşı<sup>1</sup>, Nesibe Esra Karaman<sup>1</sup>**

<sup>1</sup> Kütahya Sağlık Bilimleri Üniversitesi Tıp Fakültesi

## Özet

Dudak apsesi, dudak şişliğinin ayırıcı tanısında akılda bulundurulması gereken nadir ve ciddi bir durumdur. 35 yaşında kadın hasta, alt dudağında hızla büyüyen şişlik ve uyuşma şikayetleri ile kliniğimize başvurdu. Hasta alt dudağında ağrılı şişlik şikayeti ile acil servise başvurmuş ve herpes labialis tanısı ile antiviral tedavi almış. Ancak şikayetlerinin düzelmemesi ve dudaktaki şişliğin büyümesi nedeniyle tekrar acil servise başvuran hastaya anjiyoödem tanısı ile steroid ve antihistaminik tedavisi başlanmış. Hastanın yapılan fizik muayenesinde alt dudağı aşırı ödemli, eritemliydi ve pürülan akıntı mevcuttu. Hastanın alt dudağına acil kesi ve drenaj yapıldı. Alınan kültür sonucu metisiline duyarlı Staphylococcus aureus enfeksiyonu (MSSA) geldi. Bu yazıda MSSA nedeniyle alt dudak apsesi olan bir hastayı sunmayı amaçladık. Dudak apsesinin yanlış teşhisi ve tedavisi hastalığın ilerlemesine ve ciddi komplikasyonlara neden olabilir. Acil servise dudağında şişlik şikayeti ile başvuran hastalarda dudak apsesi mutlaka akla gelmelidir.

**Anahtar kelimeler:** Dudak, anjiyoödem apse herpes simpleks Staphylococcus Aureus

## Abstract

Lip abscess is a rare and serious condition, which should be considered in the differential diagnosis of lip swelling. A 35-year old female presented at our clinic with a rapidly enlarged swelling of the lower lip and paresthesia. It was learned that the patient had previously presented at the emergency department due to swelling of the lip and had been given local antiviral treatment with the diagnosis of herpes simplex labialis. As the complaints did not resolve, the patient presented at the emergency department again and received steroid and anti-histamine treatment with the diagnosis of angioedema. On physical examination, the lower lip was observed to be extremely edematous, erythematous and a few pustules were draining. Emergent incision and drainage was performed. Lip culture showed methicillin-sensitive Staphylococcus aureus infection (MSSA). The case is here presented of a patient with lower lip abscess caused by MSSA. Misdiagnosis and treatment of lip abscess can lead to progression of the disease and serious complications. For patients presenting with lip swelling, lip abscess should be kept in mind.

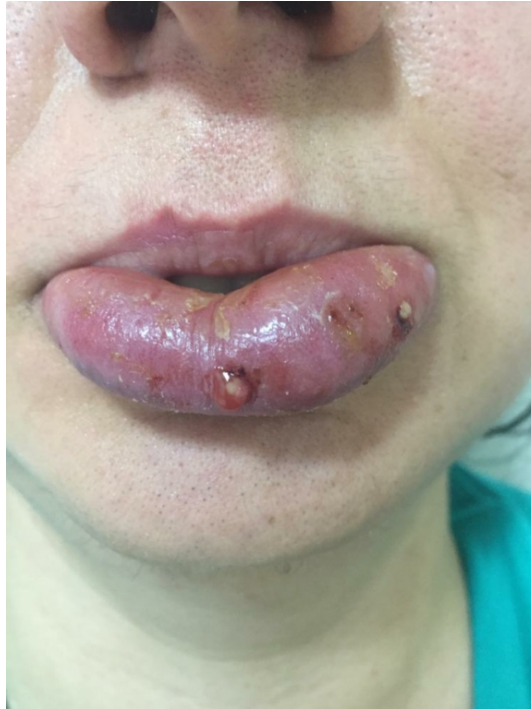**Keywords:** Lip, angioedema abscess herpes simplex Staphylococcus Aureus

## Introduction

As many local or systemic diseases can cause acute lip swelling, the differential diagnosis is extensive. Some of the pathological causes of lip swelling are infection, inflammatory, cystic, reactive, neoplastic and iatrogenic/acquired conditions[1]. Staphylococcus aureus is a gram-positive, cocci bacterium, which naturally colonizes in the nares, axilla, vagina and pharynx[2,3]. S. aureus can cause skin, soft tissue, respiratory, bone, joint, and endovascular infections and can be life-threatening. The typical pathological finding of staphylococcal disease is abscess formation[2]. Lip abscess is a rare and serious condition, which should be considered in the differential diagnosis of lip swelling. The case is here reported of a patient with a bacterial lip abscess caused by MSSA.

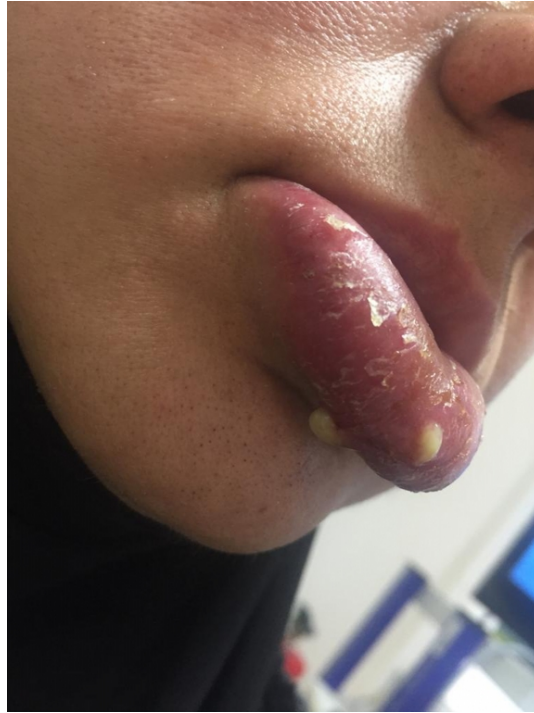
## Case Report

A 35-year old female initially presented at the emergency department due to sudden swelling of the lower lip. Herpes simplex labialis was suspected and local antiviral treatment was started in the emergency department. As the pain increased, the patient applied to the emergency department again the next day. Angioedema was considered and steroid and antihistamine treatment was initiated. Although the patient used the treatment regularly for 3 days, the swelling in the lower lip increased and paresthesia started. The patient then presented at our outpatients clinic with rapidly enlarged swelling of the lower lip and paresthesia. On physical examination, the lower lip was observed to be extremely edematous, erythematous and a few pustules were draining (Figure 1).



**Figure 1A**

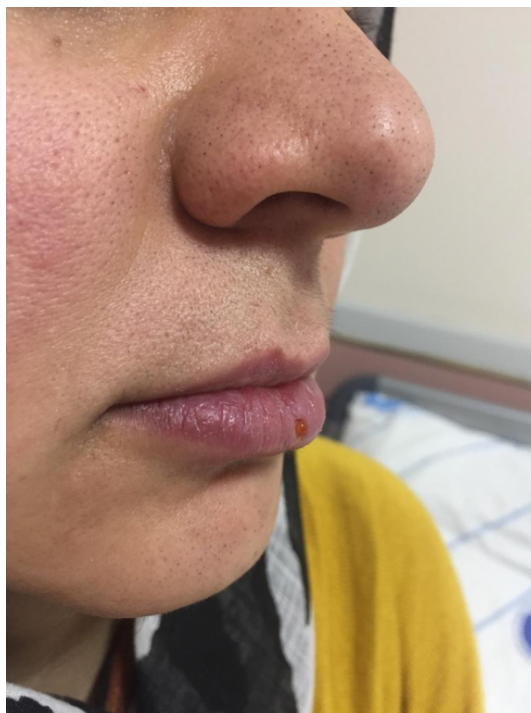Frontal clinical views of severe edema, erythema and a few draining pustules of lower lip caused by lip abscess



**Figure 1B**

lateral clinical views of severe edema, erythema and a few draining pustules of lower lip caused by lip abscess

On palpation, the submandibular and cervical lymph nodes were negative. Emergent incision and drainage was performed. Hospital admission was required for close follow up and treatment with analgesics and intravenous antibiotics. The patient was treated empirically with intravenous clindamycin, intravenous paracetamol and local application of fusidic acid. Lip culture showed methicillin-sensitive *Staphylococcus aureus* (MSSA) infection and lip abscess was diagnosed. There was no family history of angioedema and the patient had no systemic diseases or immunodeficiency. On examination, there was no edema or swelling in the uvula or larynx, no respiratory distress and the patient had no known food or drug allergies. As a result of the antibiogram, the patient was seen to be sensitive to clindamycin. Intravenous clindamycin treatment was administered to the patient for 5 days. The paresthesia disappeared and swelling decreased, so the patient was discharged with 5 days of oral amoxicillin clavulonate treatment (Figure 2). On the 10th day, it was observed that the swelling on the lips had completely disappeared.



**Figure 2**

Image of decreased swelling on the 5th day of treatment

## Discussion

The most common reasons of lip swelling are infection, angioedema and trauma [4]. Herpes labialis, varicella zoster, herpes zoster, herpes simplex viruses, syphilis, dental abscess, tuberculosis, actinomycosis, leprosy and impetigo are the infection causes of lip swelling [1]. Herpes labialis is characterized by recurrent vesicular eruptions on the lips and perioral skin. Herpes labialis is contagious, can cause severe pain, and can adversely affect the quality of life. The diagnosis of herpes labialis is mainly clinical based on classic grouped lesions such as papules, vesicles and ulcers on the lip. Antiviral agents are used in treatment [5]. Angioedema is typically characterized by non-pitting, nontender, asymmetric swelling of lips, tongue, periorbital, bowel wall and extremities and urticaria occurs in approximately 50% of cases. Idiopathic recurrent angioedema, allergic angioedema, hereditary angioedema, acquired angioedema, medication-induced angioedema (ACE inhibitors), physically induced angioedema (cold, heat, vibration, trauma, emotional stress, ultraviolet light), cytokine-associated angioedema syndrome (Gleich's syndrome), thyroid autoimmune disease-associated angioedema are the syndromes of angioedema. In the diagnosis of angioedema potential triggers such as medications, allergens, trauma and family history should be questioned.

Antihistamines and glucocorticoids are given in treatment. Epinephrine should be added if laryngeal edema is suspected [6]. The case is here presented of a patient with a bacterial lip abscess caused by MSSA initially diagnosed as herpes simplex labialis and angioedema.

There are a few publications about lip abscess in the literature. Cases of lip abscess associated with insect bite, isotretinoin treatment of acne vulgaris, and lip augmentation with silicone have been presented in the literature [4,7,8]. Early diagnosis and treatment of lip abscess is very important. Lip abscess due to staphylococcus aureus has been rarely reported in the literature. Amin et al. reported a case-series of lip infections. Lip cultures showed methicillin-resistant Staphylococcus aureus in 3 patients and MSSA in 4 patients [3]. Treatment consisted of antibiotics only or surgical intervention with antibiotics. All the lip infections were completely cured. It was emphasized that it should be considered that patients may be immunocompromised or have antibiotic resistance.

Patients with type 1 diabetes, intravenous drug users, patients undergoing hemodialysis, surgical patients, those with acquired immunodeficiency syndrome and patients with qualitative or quantitative defects in leukocyte function are at increased risk for staphylococcal disease[2]. The current case was a bacterial lip abscess caused by MSSA. The patient was sensitive to clindamycin and had no immunodeficiency, drug use and systemic disease. In a previous report in the literature, a 31-year old patient with lower lip swelling was initially diagnosed with allergic reaction and given a steroid injection and antihistamines treatment and discharged from the emergency department. Two days later the patient returned to the same emergency department with complaints of fever, chills, progressive swelling of the lower lip, abdominal pain, dyspnea, cough and anorexia. The patient died from lip abscess caused by community-acquired methicillin-resistant staphylococcus aureus infection leading to septic pulmonary emboli and necrotizing pneumonia 26 days after admission [9]. Lucerna et al. reported a case of a 21-year old male who presented with a swollen lower lip initially diagnosed as angioedema with the final diagnosis of methicillin resistant Staphylococcus aureus lip infection [10]. The authors emphasized that it is important for emergency doctors to consider lip infections as well as angioedema in a patient that presents with lip swelling. As in these two cases, the current patient was first treated for different diagnoses. In this case, herpes simplex labialis was first considered and was treated with local acyclovir in the emergency department. The lip swelling and pain increased, so the patient applied to the emergency department again the next day. Angioedema was considered and steroid and antihistamine treatment was initiated. The patient condition worsened during the following days, with enlarged swelling of the lower lip and the onset of paresthesia before admission to our clinic. There was no drug use, family history and contact with an allergic trigger in the history of patient. On examination, there was no swelling in the uvula, tongue, larynx and extremities. The lower lip was observed to be extremely edematous, erythematous and a few pustules were draining. Emergent incision and drainage was performed and culture received. Intravenous clindamycin treatment was started empirically. Lip culture showed MSSA infection. Staphylococcus aureus infections are treated with antibiotics such as penicillin, cephalosporin, clindamycin, vancomycin, fluoroquinolones, trimethoprim–sulfamethoxazole, minocycline, oxzolidinones, quinupristin–dalfopristin, chloramphenicol, gentamicin, rifampin, tetracycline, linezolid and daptomycin [2,9,10]. The current patient was treated empirically with intravenous clindamycin, intravenous paracetamol and local application of fusidic acid. MSSA was isolated from the culture. The patient, who was sensitive to clindamycin was treated for 5 days in the hospital. The paresthesia disappeared and swelling decreased. The patient was discharged with oral amoxicillin clavulanate and local fusidic acid treatment for 5 days. On the 10th day, it was observed that the swelling on the lips had completely disappeared.

## Conclusion

Lip abscess is a serious condition that can result in mortality therefore early diagnosis is very important. For patients presenting with lip swelling, lip abscess should be kept in mind.

## References

1. Ghafoor M, et al. Impetigo presenting as an acute necrotizing swelling of the lower lip in adult patient. *Oral Surg Oral Med Oral Pathol Oral Radiol.* 2012;113(6):22-24
2. Lowy FD. Staphylococcus aureus infection. *N Engl J Med.* 1998;339(8):520-532
3. Amin D, et al. Diagnosis and treatment of lip infections. *J Oral Maxillofac Surg* 2021;79(1):133-140
4. Gupta SV, et al. Lip abscess due to insect bite- A case report. *J Oral Med Surg* 2017;1(1):27-9
5. Leung AKC, Barankin B. Herpes Labialis: An Update. *Recent Pat Inflamm Allergy Drug Discov.* 2017;11(2):107-113
6. Temino VM, Peebles RS The spectrum and treatment of angioedema. *Am J Med.* 2008;121(4):282-286
7. Huoh KC, Chang KW. Lip Abscess associated with isotretinoin treatment of acne vulgaris. *JAMA Dermatol.* 2013;149(8):960-961
8. Schmidt-Westhausen AM, Frege J, Reichart PA. Abscess formation after lip augmentation with silicone:

- Case report. *Int. J. Oral Maxillofac. Surg.* 2004;33(2):198-200
9. Bruno GJ, Bruno JM, Miyake AA. Community-acquired methicillin-resistant staphylococcus aureus infection with fatal necrotizing pneumonia from lip abscess. *J Oral Maxillofac Surg.* 2007;65(11):2350-2353
  10. Lucerna AR, Espinosa J, Darlington AM. Methicillin-resistant staphylococcus aureus lip infection mimicking angioedema. *J Emerg Med.* 2015;49(1):8-11