

# A PATIENT WITH VERTIGO FOLLOWING AN IN-VEHICLE TRAFFIC ACCIDENT: WHIPLASH SYNDROME, A CASE REPORT

ARAÇ İÇİ TRAFİK KAZASI SONRASI VERTİGO: WHIPLASH SENDROMU, BİR OLGU SUNUMU  
Otoloji

Başvuru: 09.06.2022  
Kabul: 17.01.2023  
Yayın: 17.01.2023

Onurhan Güven<sup>1</sup>, Kemal Görür<sup>1</sup>, Kemal Koray Bal<sup>1</sup>, Harun Gür<sup>1</sup>, Cengiz Özcan<sup>1</sup>

<sup>1</sup> Mersin Üniversitesi Tıp Fakültesi

## Özet

Whiplash bir travma sonrası boyun bölgesine yayılan akselerasyon-deselerasyon enerji mekanizmasıdır. Whiplash travması, boyunun ani ekstansiyonu ve fleksiyonu sonrası oluşan bir çeşit servikal omurga ve yumuşak doku yaralanmasıdır. Bu yaralanmalar, whiplash ile ilişkili bozukluklar olarak adlandırılan değişken klinik belirtilere yol açabilir. Bir sendrom için genel bir terim olarak, Whiplash sendromu, özellikle seyir halindeki araca arkadan çarpılan bir trafik kazası sonrası vertigo ve dengesizlik, bulantı ve kusma, boyun ağrısı ve boyunda tutulmalar ile kulak çınlaması ve hipoakuzi gibi semptomların da görüldüğü bir klinik tablo olarak tanımlanabilir. Bizim olgumuzda, vertigo şikayeti ile kliniğimize başvuran 44 yaşında erkek hasta, emniyet kemeri takılı seyir halindeyken başka bir aracın arabasına arkadan çarpması sonucu, başının aniden öne ve arkaya doğru savrulduğunu belirtmiştir. Hasta kazadan birkaç saat sonra baş dönmesi, dengesizlik, bulantı ve kusma şikayetleri yaşamıştır. İşitme kaybı, kulakta dolgunluk hissi veya kulak çınlaması olmamıştır. Hastanın videonistagmografisi hafif sol atım spontan nistagmus, kalorik test sonuçları sağ kulakta tek taraflı güçsüzlük olduğunu göstermiştir. Klinik bulgular ve anamnez dikkate alınarak hastaya vertigosu sebebiyle whiplash sendromu tanısı konulmuştur. Bu olgu sunumu whiplash travması sonrası vertigo gelişen bir hastanın klinik tablosunu, tanısını ve tedavisini tartışmak amacıyla sunulmaktadır.

**Anahtar kelimeler:** vertigo, dengesizlik whiplash sendromu whiplash travması trafik kazası

## Abstract

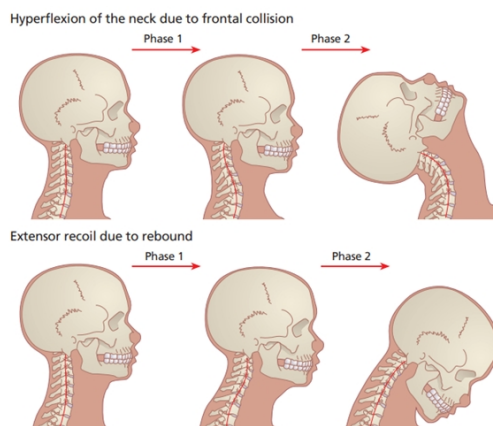
Whiplash is an acceleration-deceleration mechanism of energy transfer to the neck. Whiplash trauma is an injury of the cervical spine and soft tissue that occurs after sudden extension and flexion of the neck. As a general term for a syndrome, Whiplash syndrome can be defined as comprehended symptoms such as vertigo and disequilibrium, nausea and vomiting, neck pain and stiffness, tinnitus and hypoacusia, etc. following a traffic accident, especially rear-end collisions. We present a case report of a 44-year-old male patient who complained of vertigo after a car accident. His head was suddenly thrown backward and forwards during the collision of another vehicle to the back of his car while he was driving with his seat belt fastened. The patient suffered from the symptoms of vertigo, disequilibrium, nausea, and vomiting a few hours after the accident. No hearing loss, aural fullness, or tinnitus. On videonystagmography, the patient had mild left-beating spontaneous nystagmus, caloric test results showed unilateral weakness in the right ear. Considering the clinical findings and history, the patient was diagnosed with vertigo and whiplash-associated disorder. We present this case report to discuss the clinical picture, diagnosis, and management of a patient who had vertigo following whiplash trauma.

**Keywords:** vertigo, dizziness whiplash syndrome whiplash trauma traffic accident

## Introduction

Whiplash injury is the trauma of cervical spine that occurs due to a sudden back and forth movement of the head during an in-vehicle traffic accident, particularly when the seat belt is fastened (Figure 1). Persistent headache, neck pain, vertigo, disequilibrium, nausea, and vomiting may be seen in 15-20% of cases after whiplash trauma,

and the presentation characterized by those symptoms is called “whiplash syndrome” [1-4]. Deterioration of neural transmission between the cervical proprioceptive system and the central vestibular system has been suggested as the cause of disequilibrium and vertigo. The aim of this case report is to discuss the clinical picture, diagnosis and management of a patient who had vertigo following whiplash trauma.



**Figure 1**

Formation of whiplash trauma. \*Jaye et al, 2004

## Case Report

A 44-year-old male patient was admitted to our clinic with vertigo that started after an in-vehicle traffic accident. Vertigo had been continuing for five days. His head was suddenly thrown backward and forwards during the collision of another vehicle to the back of his car while he was driving with his seat belt fastened. The patient had vertigo, disequilibrium, nausea, and vomiting a few hours after the accident. He did not have neck pain or headache. He applied to the physician and was prescribed betahistine dichloride and dimenhydrinate. The patient’s complaints continued, and he applied to the emergency department. His electrocardiogram and cerebral magnetic resonance imaging (MRI) were normal, he was prescribed symptomatic medications. The patient was admitted to our clinic five days after the accident with the same complaints. The patient did not complain of hearing loss, aural fullness or tinnitus. The patient did not have any chronic disorders or use any regular medications.

The otoscopic examination, tympanogram, and pure tone audiogram were normal (Figure 2). Dix-Hallpike test, supine roll test, Romberg, and skew tests were negative, and the video head impulse test was normal (Figure 3). On videonystagmography (VNG), the patient had mild left-beating spontaneous nystagmus, caloric test results showed unilateral weakness in the right ear (Figure 4, 5). Temporal bone computed tomography, cerebral magnetic resonance imaging, and Doppler ultrasonography of vertebral arteries (USG) were reported as normal.

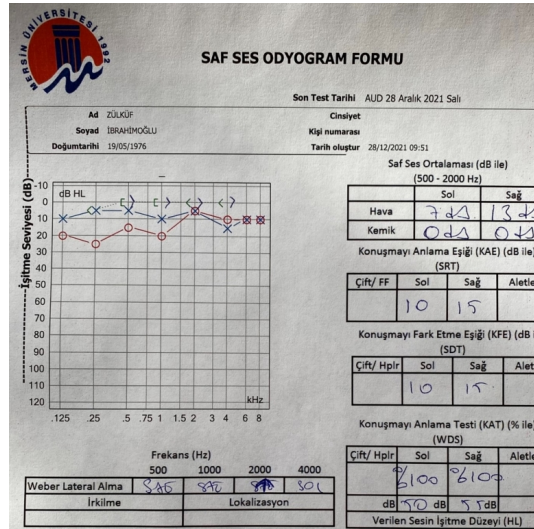


Figure 2

Normal hearing thresholds on pure tone audiogram.

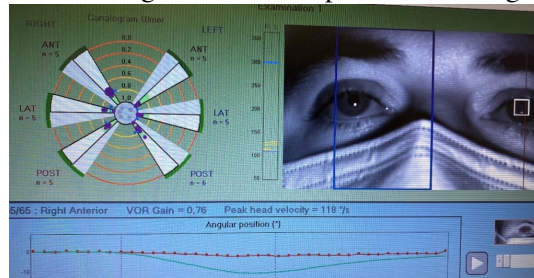


Figure 3

Video head impulse test results, bilateral semicircular canal gains are normal.

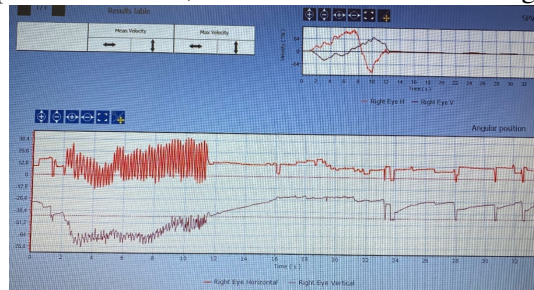


Figure 4

Videonystagmography results, mild left-beating spontaneous nystagmus.

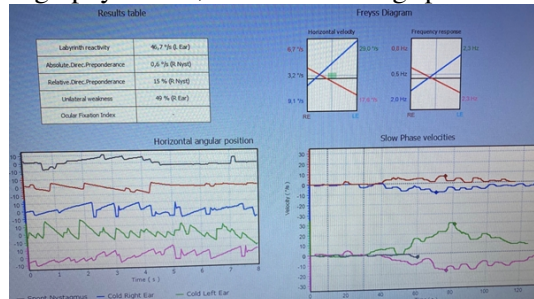


Figure 5

Caloric test results, right unilateral hypofunction.

Considering the clinical findings and history, the patient was diagnosed with vertigo and whiplash-associated

disorder after whiplash trauma. Single-dose intravenous 1 mg/kg methylprednisolone was administered at the time of admission, and betahistine dichloride 48 mg/day was prescribed as the symptomatic treatment. The patient's complaints disappeared within two months of follow-up.

**Informed Consent:** Informed consent was obtained from the patient involved in this study.

## Discussion

Whiplash is an acceleration-deceleration mechanism of energy transfer to the neck. Whiplash trauma is an injury to the cervical spine and soft tissue. The name of "Whiplash trauma" was first used in a symposium about traffic accidents in San Francisco by Crowe in 1928. It occurs during rear-end car accidents, particularly when the seat belt is on, due to rapid and forceful back-and-forth movement of the head forcing the neck joints to over flexion and overextension, beyond the normal range of motion [1-4].

According to the analysis of The Quebec Task Force, neck pain and limitation of the movement were deemed necessary after whiplash injury for the diagnosis of whiplash syndrome [2]. It has been classified in the category of whiplash-associated disorders about the post-traumatic symptoms. In most cases, balance problems or vertigo may be evident in the acute or late periods after the injury.

Whiplash-associated disorder (WAD) is a term for a soft tissue injury of the neck with symptoms such as neck pain and stiffness, headaches, dizziness, visual symptoms, cognitive and psychiatric disorders, paresthesias, and weakness. Many patients after whiplash injury recover fast, but, between 4 and 42 % of patients can suffer from symptoms several years later the trauma. Dizziness can be seen in 70% of patients with whiplash injuries [2,3].

Literature data indicates that post-traumatic balance and hearing problems may occur in 5-50% of the individuals who had whiplash trauma [1].

Although the pathophysiologic mechanisms of imbalance and vertigo have not been clearly defined, vertigo and disequilibrium occur mainly due to damage to the neck joints, cervical vasculature, neck muscles, or neck ligaments after trauma, affecting the cervicospinal proprioceptive signal pathway which is associated with the central vestibular system [5]. Not only a direct effect of the trauma in the inner ear but also damage to vessels supplying the inner ear have also been suggested for the reason of vertigo [4]. Ischemia due to vertebral artery compression, hemorrhage, concussion of the labyrinth, or acoustic trauma due to noise during collision has also been accused as possible causes [3,4]. In Ommaya's hypothesis, an abnormal stretching of the cerebrum, and sudden transient increase of the pressure cerebrospinal fluid that cause neuropsychological symptoms after whiplash trauma provoked a commotio cerebri with potential injuries to the temporal cortex, amygdala, hippocampus, medial temporal cortex, corpora mammillaria, medial thalamus, basal nuclei, prefrontal cortex, and retrosplenial cingulate cortex [2,6].

Differential diagnosis of vertigo due to whiplash trauma should be considered with clinical evaluation of peripheral labyrinthine pathways and vestibuloocular reflex arc by using clinical vestibular tests, videonystagmography, and caloric tests [2,7].

The meta-analysis of Favaretto et al. including 700 cases reported the most frequent symptoms as disequilibrium, positional symptoms, and neck pain. Impaired vestibuloocular reflex, spontaneous nystagmus, and bilateral vestibular hypofunction were frequently observed on VNG. The authors suggested that VNG and caloric tests were helpful in the diagnosis [4].

Endo et al. detected unilateral vertebral artery occlusion on neck MRI angiography and unilateral slow vertebral

artery flow on Doppler USG in a patient who had headache, neck pain and dizziness that were present for months after whiplash trauma [7].

BPPV may also be seen after whiplash trauma, and it should be included in the differential diagnosis of vertigo, particularly if the patient has a history of head trauma [3,8].

In the treatment of vertigo following Whiplash trauma, symptomatic therapy involves vestibular suppressors and antiemetic drugs are suggested. Antihistaminic drugs such as dimenhydrinate, flunarizine, cinnarizine, hydroxyzine, and betahistine can be used immediately and continued for a few days. Benzodiazepines can also be used for inhibitory effects on vestibulocerebellar pathways and vestibular nuclei by GABAergic activation. Benzodiazepines should be carefully administered in elderly patients to avoid respiratory inhibitor effects [2].

## References

1. Tranter RM, Graham JR. A review of the otological aspects of whiplash injury. *J Forensic Leg Med.* 2009 Feb;16(2):53-5.
2. Pallestrini E.A, Castello E., Garaventa G. Pharmacological treatment of Whiplash-Associated Disorders (WAD). In: Alpini DC, Brugnoli G, Cesarani A, eds. *Whiplash Injuries: Diagnosis and Treatment.* 2nd ed. Milan, Italy: Springer; 2014:259-268.
3. Dispenza F, De Stefano A, Mathur N, Croce A, Gallina S. Benign paroxysmal positional vertigo following whiplash injury: a myth or a reality? *Am J Otolaryngol.* 2011 Sep-Oct;32(5):376-80.
4. Favaretto N, Lionello M, Boscolo-Berto R, Giacomelli L, Rondinelli R, Marioni G. Video-nystagmographic evidence in more than 700 consecutive cases of road traffic whiplash injury. *Am J Otolaryngol.* 2021 May-Jun;42(3):102909.
5. Jaye C. Managing whiplash injury. *Emerg Nurse.* 2004 Nov;12(7):28-33. doi: 10.7748/en2004.11.12.7.28.c1172
6. Caserani A, Claussen C.F., Alpini D.C. Whiplash: An interdisciplinary challenge. In: Alpini DC, Brugnoli G, Cesarani A, eds. *Whiplash Injuries: Diagnosis and Treatment.* 2nd ed. Milan, Italy: Springer; 2014:1-9.
7. Endo K, Ichimaru K, Komagata M, Yamamoto K. Cervical vertigo and dizziness after whiplash injury. *Eur Spine J.* 2006 Jun;15(6):886-90.
8. Katsarkas A. Benign paroxysmal positional vertigo (BPPV): idiopathic versus post-traumatic. *Acta Otolaryngol* 1999;119:745-9