

# BILATERAL GIANT RHINOLITHIASIS CAUSING NASAL SEPTAL PERFORATION

NAZAL SEPTAL PERFORASYONA NEDEN OLAN BİLATERAL DEV  
RİNOLİTİYAZİS  
Rinoloji

Başvuru: 07.12.2023  
Kabul: 14.02.2024  
Yayın: 14.02.2024

Murat Yaşar<sup>1</sup>, Fatih Öner<sup>1</sup>

<sup>1</sup> Kastamonu University, School of Medicine

## Özet

Rinolitiazis, burun boşluğunda yabancı cisimlerin etrafında kalsifiye materyalin birikmesiyle oluşan bir klinik durumdur. Sıklıkla ön burun boşluğunda görülür ve tıkanıklığa neden olacak kadar büyüyene kadar asemptomatik olabilir. Rinoliti olan hastalar kronik burun akıntısı, baş ağrısı, yüz rahatsızlığı, hoş olmayan burun kokusu, ağız kokusu, anozmi, burun tıkanıklığı ve periyodik burun kanaması şikayetleri ile başvururlar. Bu makalede, burun içi tümörü taklit eden ve burun mukozasına ve septum kıkırdağına zarar vererek septal perforasyona neden olan bilateral yerleşmiş rinolitinin cerrahi olarak çıkarılması literatür eşliğinde tartışılmıştır.

**Anahtar kelimeler:** Burun tıkanıklığı, endoskopik burun cerrahisi; rinolitiazis septal perforasyon

## Abstract

Rhinolithiasis is a clinical disorder characterized by the deposition of calcified material in the nasal cavity around foreign items. Rhinoliths are frequently seen at the front of the nasal cavity and might be asymptomatic until they grow large enough to cause obstruction. Rhinoliths are typically characterized by chronic runny nose, headache, face discomfort, unpleasant nasal odor, halitosis, anosmia, nasal congestion, and periodic nosebleeds. This article describes the surgical removal of a bilateral massive rhinolith that mimicked an intranasal tumor and caused septal perforation by damaging the nasal cavity mucosa and septum cartilage.

**Keywords:** Endoscopic nasal surgery, nasal obstruction Rhinolithiasis Septal perforation

## Introduction

Rhinolithiasis is a clinical condition that occurs with the formation of calcified material around foreign bodies in the nasal cavity. It was first described in 1654 by Dr. Thomas Bartholin, and its first chemical analysis was made by Axmann in 1829. [1, 2] Rhinolith, usually seen in children, can occur around endogenous body tissues such as teeth, blood clots, de-squamated epithelium, bone fragments, or around exogenous foreign objects such as stones, insects, or wood. A chronic inflammatory reaction is triggered by the deposition of mineral salts such as calcium phosphate, calcium carbonate, and magnesium phosphate around the foreign body [2].

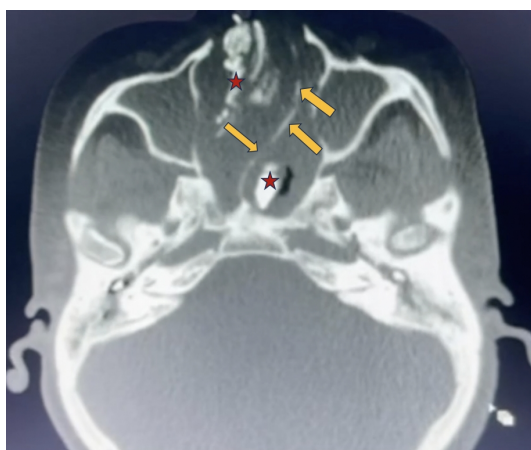
Rhinoliths are often located in the front of the nasal cavity, and sometimes, they can remain asymptomatic while they grow large enough to cause obstruction [2, 3]. Symptoms of rhinoliths usually include persistent runny nose, headache, facial pain, foul nasal odor, halitosis, anosmia, nasal congestion, and intermittent nosebleeds. Anterior rhinoscopic examination or imaging methods can make the diagnosis. Since most rhinoliths have a radiopaque appearance, they can be easily recognized and localized using conventional X-rays. Computed tomography (CT) may be necessary to determine the size and location of low-radiodense rhinoliths or before surgery. [4]

This article presents a bilateral huge rhinolith, which was surgically removed under general anesthesia, mimicking an intranasal mass and causing septal perforation by destroying the nasal cavity mucosa and septum cartilage.

## Case Report

A 54-year-old female patient with mild mental retardation was brought to the Otorhinolaryngology outpatient clinic by her relatives with complaints of ear fullness and hearing loss. Otoscopic examination revealed that both tympanic membranes were retracted. A mass that completely filled the right nasal cavity was detected on examination of the nasal cavity with a rigid endoscope. It was observed that the mass covered with purulent secretion pushed the nasal septum entirely to the left, obliterating it to a level that did not allow the rigid endoscope to pass through the left nasal cavity. When examined from the oropharynx to the nasopharynx using a 70° angled rigid endoscope, it was determined that the mass filled the nasopharynx. It was learned that the patient, who had no known history of trauma or nasal surgery, could not breathe comfortably through her nose since she was a child. Her relatives reported that she had a foul-smelling, excessive runny nose, nasal congestion, cough, and a habit of constantly clearing her throat and wiping her nose for a long time. The patient, who had never been to an otolaryngologist with these complaints before, was diagnosed with asthma in a center where she applied with complaints of shortness of breath and was started on medications, and she had been receiving asthma treatment for the last two years.

The CT scan of the patient showed a mass and pansinusitis findings compatible with highly hyperintense rhinoliths obliterating almost the entire right nasal cavity and the posterior half of the left nasal cavity. It was determined that the nasal septum was pushed up to the left lateral nasal wall by the mass effect of the rhinolith on the right side (Figure 1).

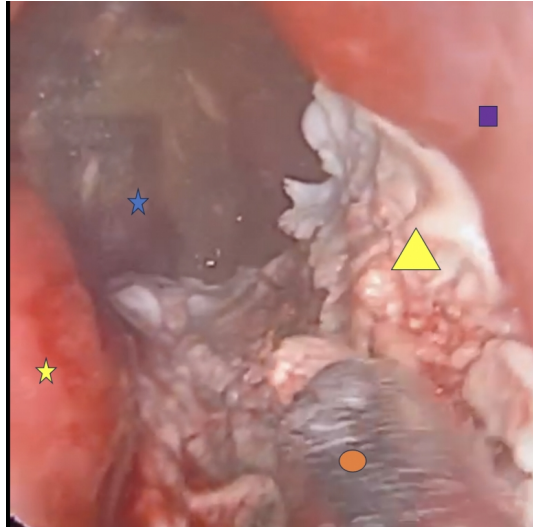


**Figure 1**

Image of rhinolith filling both nasal cavities and deviating the nasal septum to the left on the patient's axial section paranasal CT. Yellow arrows; the nasal septum, Red stars; images of hyperintense rhinoliths in both nasal cavities

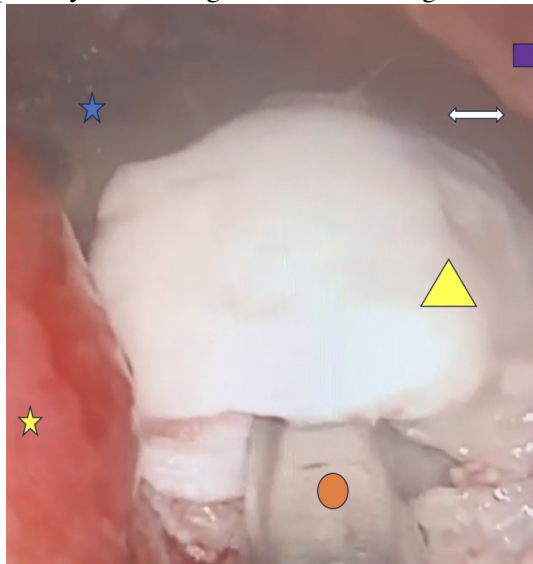
While normal hearing threshold levels were obtained in the audiometric examination, tympanometry revealed a bilateral type C tympanogram.

Endoscopic sinus surgery was planned under general anesthesia. The rhinolith in the right nasal cavity was removed piece by piece endoscopically. After removing the rhinolith, purulent secretion from the osteo-meatal complex was observed to drain into the nasal cavity. There was pressure atrophy in the middle and inferior turbinate and three perforated areas in the bone septum, the largest of which was 2x2 cm, and the others 1x1 cm. The nasal mucosa in contact with the rhinolith appeared extremely fragile and degenerated. The left nasal cavity could be visualized by making a hemitransfixion incision in the caudal septum mucosa and removing the anterior deviated cartilage parts. Endoscopically, the rhinolith in the left nasal cavity was removed piece by piece (Figure 2- 3).



**Figure 2**

Removal of rhinolith in the right nasal cavity. Blue star; nasopharynx, yellow star; inferior turbinate, purple square; nasal septum, yellow triangle; rhinolith, orange circle; suction.

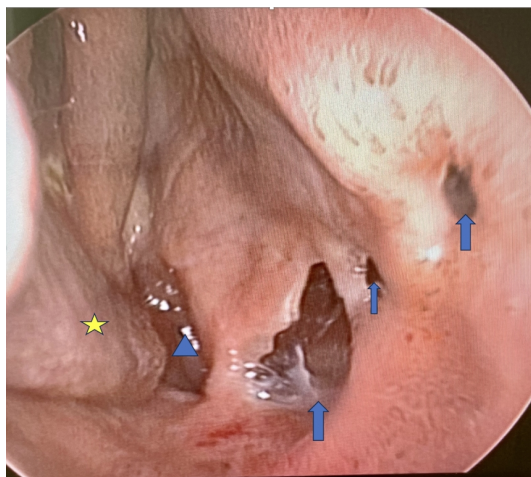


**Figure 3**

Image of rhinolith in the right nasal cavity with perforation in the septum. blue star; nasopharynx, yellow star; inferior turbinate, purple square; nasal septum, yellow triangle; rhinolith, orange circle; suction, two-way white arrow; septal perforation area.

The histopathology was reported as chronic necrotic inflammatory rhinolith.

At the postoperative follow-up, it was observed that the patient's nose and ear complaints had improved, the infection findings in the nasal mucosa had disappeared, the eardrums appeared normal, the pressure values had returned to normal in the tympanometric examination (Tympanogram Type A), but the septal perforations persisted (Figure 4).



**Figure 4**

Image of the right nasal cavity at the third post-operative week. In the image, it is seen that the mucosa has almost completely healed, the purulent secretions have disappeared, and the perforations in the nasal septum persist. Blue triangle; Nasopharynx, Yellow star; Right inferior turbinate, Blue arrows; It shows perforated areas in the nasal septum.

The patient was scheduled for surgery to repair the septum perforation. It was learned that they stopped taking their asthma medications because their complaints of shortness of breath had resolved.

## Discussion

In our article, we presented a case of complicated rhinolith perforating the nasal septal mucosa and cartilage, which we thought occurred long ago in the nose. The pathogenesis of rhinoliths is unclear, but several factors are thought to play a role in rhinolith formation. These include foreign bodies trapped in the nasal cavity, acute and chronic inflammation, obstruction and stagnation of nasal secretions, and precipitation of mineral salts. A foreign body in the nasal cavity hardens with the accumulation of elements such as iron, aluminum, calcium, and magnesium around it due to a chronic inflammatory response, causing rhinolith formation [5,6]. An extended period is usually required for rhinoliths to form. The fact that the rhinolith in our patient reached a size that filled the bilateral nasal cavities and even the nasopharynx suggested that it was due to the clinical condition of mild mental retardation.

Rhinoliths are usually unilateral and single [7]. Patients generally present with complaints such as nasal congestion, unilateral rhinorrhea, head and facial pain, toothache, foul-smelling nasal discharge, bad breath, anosmia, and recurrent nosebleeds. Some cases are asymptomatic and found incidentally [2,8]. Due to the generally inadequate self-care of mentally disabled patients, their complaints of foul-smelling nasal discharge are ignored by their relatives and caregivers. In our case, although there were similar complaints, the patient and her relatives were not disturbed by the situation and did not visit a doctor until the complaint of ear-related congestion occurred.

Sinusitis, septal deviation, and mucosal thickening are the most common nasal pathologies associated with rhinolith [7]. Other reported complications include septal perforation, frontal osteomyelitis, and, which are rarer and more vital, epidural abscess formation [8,9]. In our patient, the rhinolith on the right side formed and grew, deviated, and then perforated the nasal septum and continued to grow on that side by engaging the left nasal cavity. If it is not diagnosed, it could continue to grow and cause more severe complications.

The differential diagnosis of rhinoliths includes nasal polyps, calcified angiofibroma, ossifying fibromas, granulomatous disease, fungal ball, nasal actinomycosis, ectopic tooth, osteoma, chondrosarcoma, osteosarcoma,

and sino-nasal malignancies [10-13.] No fungus was found in the histopathological examination of the foreign bodies removed from our patient. While endoscopic nasal cavity examination is generally sufficient for diagnosis, since many diseases can be confused in the differential diagnosis, it would be appropriate to perform paranasal CT on patients to guide treatment planning and reduce the risk of complications that may occur during the possible surgical procedure. As in our patient, CT helps the ENT physician determine the rhinolith's location, size, and extent. It also allows us to evaluate the size of the rhinolith and the presence of additional paranasal diseases.

Treatment of rhinolith is surgical removal, usually done endoscopically under general anesthesia. The endoscopic approach is usually sufficient; lateral rhinotomy is rarely required. The surgical approach varies depending on the location, size, and presence of complications of the rhinolith. In our case, the patient was reformed to health by endoscopic removal of the rhinolith and sinus surgery.

## References

1. Nguyen J, Omiunu A, Patel R, Patel P, Fang CH, Eloy JA. Endoscopic management of rhinolithiasis: A systematic review. *Otolaryngol Head Neck Surg* 2023;168(6):1338-45. <https://doi.org/10.1002/ohn.230>.
2. Noh KB, Sachlin IS, Gazali N, Shukri NM. Giant rhinolith: A case report. *Egypt J Ear Nose Throat Allied Sci* 2017;18:155-7. <https://doi.org/10.1016/j.ejenta.2016.09.005>
3. Ersözlü T, Gültekin E. Rhinolith in the concha bullosa as a rare location: a case report. *J Int Med Res* 2020; 48(8): 0300060520951019. <https://doi.org/10.1177/0300060520951019>.
4. Singh RK, Varshney S, Bist SS, Gupta N, Bhatia R, Kishor S. A case of rhinolithiasis. *Online J Health Allied Scs* 2008;7(2):7.
5. Ezsiás A, Sugar AW. Rhinolith: an unusual case and an update. *Ann Otol Rhinol Laryngol* 1997;106(2):135-8. <https://doi.org/10.1177/0003489497106002>
6. Prasad V, Shenoy VS, Rao RA, Kamath PM, Sowmya V. A giant rhinolith: an unusual entity. *Online J Otolaryngol* 2016; 6(1): 1-5.
7. Hsiao JC, Tai CF, Lee KW, Ho KY, Kou WR, Wang LF. Giant rhinolith: A case report. *Kaohsiung J Med Sci* 2005;21:582-5. [https://doi.org/10.1016/S1607-551X\(09\)70212-8](https://doi.org/10.1016/S1607-551X(09)70212-8).
8. Girgis S, Cheng L, Gillett D. Rhinolith mimicking a toothache. *Int J Surg Case Rep* 2015;14:66-8. <https://doi.org/10.1016/j.ijscr.2015.06.031>.
9. Aksakal C. Rhinolith: Examining the clinical, radiological and surgical features of 23 cases. *Auris Nasus Larynx*. 2019;46(4):542-7. doi: 10.1016/j.anl.2018.12.008.
10. Pacheco PC, Busquets JM. A 44-year-old Rhinolith: A case report and review of the literature. *P R Health Sci J*. 2015;34(2):105-7.
11. Zhang H, Tao M, Bai J, Du S. Ectopic nasal tooth mimicking recurrent rhinolith in a young woman: A diagnostic challenge for the otolaryngologist. *Asian J Surg* 2023;46(8):3120-1. doi: 10.1016/j.asjsur.2023.02.076.
12. Bhandarkar AM, Kudva R, Damry K, Radhakrishnan B. Fungus ball in the nasal cavity mimicking a rhinolith. *BMJ Case Rep* 2016:bcr2016215490. doi: 10.1136/bcr-2016-215490.
13. Kim SD, Kim DS, Choi KU, Cho KS. Nasal Cavity Actinomycosis Mimicking Rhinolith. *J Craniofac Surg* 2018;29(3):e255-e257. doi:10.1097/SCS.0000000000004304.